71 - KNOWLEDGE OF STUDENTS OF 1 TO 4 TIMES ON THE ANATOMY AND SYSTEMIC LOCOMOTOR, UNIVERSITY VEIGA DE ALMEIDA CABO FRIO RJ.

JOSÉ AUGUSTO NOGUEIRA TRINDADE
JAUNILSON FRANCISCO DA CRUZ
UNIVERSIDADE VEIGA DE ALMEIDA, CABO FRIO, RJ, BRASIL.
jau.f.cruz@hotmail.com

Students who come to our universities bring their experiences and they can contribute positively to their learning or not. The experiences during the first year in the universities are very important for the persistence in higher education and academic success of students (Pascarella & Terenzini, 2005; Reason, Terenzini & Domingo, 2006). What is surprising is the difficulty some students understand the lessons and anatomical structures at the beginning of each semester when the course is presented to them. And what is more surprising, and this fact is that some students remain with this difficulty after going through the discipline of anatomy systemic and locomotor. Concerned about this Fornaziero, (2003), pointed technological innovations to be used to make learning more interesting Anatomy and contribute to the quality of the teaching of anatomy. Therefore, a doubt arose that sought to remedy this research: that knowledge in anatomy students arrive at Brazilian universities? This is the main focus that prompted the implementation of such research in order to identify the knowledge of students from 1st to 4th periods of Veiga de Almeida University Campus Cabo Frio RJ , compared to classes and anatomical structures.

The teacher who works with the discipline of human anatomy, realize in their daily practice that does not have as much progress in his teaching because despite the advanced technology, bones, muscles and tendons are still bones, muscles and tendons. It is perceived that the teaching of human anatomy, despite the evolution of technology and teaching methods, no major changes. Stacciarini and Esperidião (1999) state that the content was and continues to be made mostly of expository for, which creates a restriction on the use of other mechanisms for the implementation of teaching, which does not make the critical student. Even with the use of technological resources, such as multimedia projectors, not reached the practical reality of the students.

Costa (2007 and Horne et al. 1990) reported that the structure of classes in human anatomy presents two distinct periods: the theoretical part, which introduces concepts and definitions of the systems and organs of the human body and practical part, which utilizes is usually natural anatomical specimens in the laboratory, making the study of the general characteristics and their inter - relationships.

As reported by Guimarães and Silva (2004), the faculty is responsible for providing academic moments of appreciation, knowledge and awareness of body structures, formed by biological, stimulating them to a relationship with contents of anatomy and his own being biological.

But the application model of discipline may interfere with student learning. Piazza (2012) conducted a survey which investigated the possible causes of truancy and exclusion in the discipline of Human Anatomy courses in Physical Education (Degree and Bachelor's), the Methodist University of IPA. The research raised issues and implications with respect to the method of teaching the subject teacher and compared the traditional method of teaching human anatomy with the most current and innovative methods. You can find that a different method of teaching Human Anatomy prevents students feel excluded or abandon the discipline.

Perreira et al (2007) found the teaching of Human Anatomy course in Biology at the University Pompeu Fabra in Barcelona and found that students demonstrated an increase in the satisfaction of learning when the teacher used new teaching strategies, such as using the internet, slides in high definition and other multimedia materials, without leaving aside the blackboard, books and classes in cadavers. Thus there was an increase in the adoption of the students in the discipline. McLachlan and Patten (2006) tell us that the human anatomy is widely appreciated, being among the most important components of medical education. The study using cadavers dissected is seen as the best alternative medicine courses, for example.

Through teaching and learning in human anatomy, Damasceno (2003) sought to examine aspects of the organization of teaching discipline Human Anatomy Physiotherapy courses, such as assessment, workload and teaching methodology, specifically the one used in practical classes. Sixteen teachers from two universities completed a questionnaire with open questions about the topics mentioned. The results showed that teachers have a traditional approach to learning as memorizing and fixing the content, although they believe that knowledge of human anatomy is essential to professional performance that exceeds the conventional and routine procedures.

Wood (2008) considers that the human anatomy is the discipline foundation of all clinical disciplines, so a discipline essential for health.

The goals of teaching human anatomy are needed to know the anatomy and the relationships between them; recognize anatomical structures through imaging techniques and understand the anatomical basis of disease. CORREDERA and SANTANA (2003).

The study of anatomy characterized by a regional subdivision of the human body and topography, followed by the description: (PIATTO; BATIGÁLIA, 2000).

The anatomy (Anatome = cut into pieces, separating cut) so defined because it refers to the study of the structure and the relationships between these structures. Anatomy is a science that studies the physical structure of living beings. The internal and external organs, their interactions, operation, location and layout are the main aspects studied by anatomy. Already Anatomy focuses on the study of the human body and is considered one of the basic sciences of medicine. (Dangelo and Fatinni, 2007).

The Macroscopic anatomy studies the human body and as the focus receives several names: OR DESCRIPTIVE SYSTEMATIC ANATOMY: study analytically (separation of a whole into its elements or component parts) and separately the various structures of the systems that constitute the body, skeleton, the muscles, circulatory etc.; Surveying or Regional Anatomy: studies in a synthetic way (method, process or operation of bringing together different elements and merge them into a whole), the relationship between the structures of the regions bounded body; Anatomy of Surface or Alive: studying the projection of organs and structures deep in the body surface, is of great importance for the understanding of clinical semiology (study and interpretation of the set of signs and symptoms observed in the examination of a patient); Functional Anatomy: studying functional segments of the body, establishing reciprocal relationships and functions of various structures of different systems; Applied Anatomy - stresses the importance of anatomical knowledge to medical activities, medical or surgical, and even for

artistic; Radiological Anatomy: studying the body using the properties of X-rays and constitutes, with the Surface Anatomy of the morphological basis of clinical examination techniques; Comparative Anatomy: studying the anatomy of different animal species with particular focus on the ontogenetic development (development of an individual from conception to adulthood) and phylogenetic (evolutionary history of a species or any other taxonomic group) of different organs.

For the anatomical study of the human body, the material used is the corpse or corpse parts. Currently, knowledge must be transposed directly to the practical use and clinical student, making it feasible to use synthetic anatomical models, specific software, imaging and surface anatomy, approaching the basic content of the specific. The word corpse is an old Latin acrostic, Caro date vermibus which means flesh given to worms. To be handled in the classroom, the play deserves respect and care, such as the legacy transmitted by Karl von Rokitansky (1804-1878), physician and scholar of pathological anatomy. Dissector obsessive, he left us one of the maxims of anatomy: the unknown corpse meditation (Leandro, 2010).

The following structures were separated for this search: heart, spleen, thyroid, kidney, carpal bones, fibula, radio, clavicle, femur, rotator cuff, biceps, supinator, quadriceps, pectineus, tarsal bones, cremaster muscle, tibia and deltoid.

The heart is located in the thoracic cavity, between the 2nd and 5th ribs, between the lungs, with 2/3 to the left, the apex downwards and base upwards and left and right in a region called the middle mediastinum. Its apex is slightly anterior while the base slightly posterior position. The spleen is located in the upper left abdomen under the diaphragm and behind the lower ribs and costal cartilages (JACOB STANLEY W et/al.1990).

The human thyroid is composed of two lobes that are disposed on either side of the trachea and in the middle line are connected by a thin neck, which extends on the anterior surface of the trachea. (DANGELO and FATTINI, 2007).

The kidneys are located in the dorsal part of the tummy, abdominal peritoneum after just below the diaphragm, one on each side of the spine at this position is protected by the lower ribs and also a layer of fat. The poles are above the level of the upper edge of the 12th thoracic vertebra, and the poles below the level of the 3rd lumbar vertebra. The right kidney is usually lower than the left, possibly because of its close relationship with the liver. (JACOB STANLEY W et/al.1990)

The carpal bones are located in the hand. Eight bones distributed in two rows: proximal and distal. Proximal row: Scaphoid, Lunate, Pyramidal and pisiform and distal row: Trapezium, Trapezoid, Capitate, Hamato. (MIRANDA, 2000).

The thin fibula is located in the leg, posterior- laterally to the tibia and serves mainly for fastening muscles. It has no weight bearing function. Articulates with the tibia (proximally and distally) and the talus distally.

The radius is the lateral bone of the forearm. It is the shorter of the two bones of the forearm. Articulates proximally with the humerus and ulna and distally with the ulna and the carpal bones. It has two epiphyses and a shaft.

The clavicle forms the ventral portion of the shoulder girdle. It is a long bone curved like an "S" italic, located almost horizontally just above the first rib. Articulates medially with the manubrium of the sternum and laterally with the acromion of the scapula. Has two ends, two sides and two edges.

The femur is the longest bone in the body and heavy. The consists of a femur diaphysis and epiphysis two. Articulates proximally with the hip bone and distally to the patella and tibia. Except for the femur, the tibia is the largest bone in the body that supports weight. Is located on the anteromedial leg. It has two epiphyses and a shaft. Articulates with the femur proximally and distally to the fibula and talus and fibula.

The rotator cuff is comprised of four muscles located in the shoulder joint. The main function of this group is to keep the humeral head against the glenoid cavity, strengthen the joint capsule and actively resist and unwanted displacements of the humeral head anteriorly, posterior and superior.

Are the following muscles: supraspinatus, with medial insertion in the supraspinatus fossa on the scapula, lateral insertion on the superior facet of the greater tubercle of the humerus innervation: Supra scapular nerve (C5 and C6) and Action: Abduction of the arm; Infra Spinal - with medial insertion in the infraspinatus fossa of the scapula, lateral insertion on the middle facet of the greater tubercle of the humerus innervation: Supra scapular nerve (C5 and C6) and action: lateral rotation of the arm; Smaller Round with medial insertion: 2/3 of the upper lateral border of the scapula, lateral insertion: inferior facet of the greater tubercle of the humerus innervation: Axillary nerve (C5 and C6) and action: lateral rotation and adduction of the arm and subscapular, medial insertion with the subscapular fossa, lateral insertion on the lesser tubercle, innervation: Upper and Lower subscapular nerve - Volume posterior (C5 and C6) and action: medial rotation and adduction of the arm. (JACOB STANLEY W et/al.1990; MIRANDA, 2000; DANGELO and FATTINI, 2007).

The deltoid muscle has its origin on the spine of the scapula, acromion and the lateral third of the clavicle and inserting in deltoidea or "V" deltoid. Innervation is Axillary nerve (C5 and C6), with the following actions: abduction of the arm assists in flexion, extension, lateral and medial rotation, flexion and extension of the horizontal arm. Stabilization of the shoulder joint. (JACOB STANLEY W et/al.1990; MIRANDA, 2000; DANGELO and FATTINI, 2007).

The method used was through a questionnaire where students had access to 18 questions on the gross anatomy of the human body and scored on a figure that was with some squares and the same would have to mark the box in an "X " corresponding to the correct question. The questions are related to the following structures: heart, spleen, thyroid, kidney, carpal bones, fibula, radio, clavicle, femur, rotator cuff, biceps, supinator, quadriceps, pectineus, tarsal bones, cremaster muscle, tibia and deltoid.

The research took place in all classes of health Veiga de Almeida University, campus Cabo Frio RJ. 273 students took part, as follows: 76 students of Physiotherapy of the morning and night, 136 students of Nursing of the morning and evening and 61 students of Physical Education of the morning and evening.

Regarding classes of Physical Education, Nursing and Physiotherapy in the early years, we obtained the following results for the number of hits for each question: For the 76 students of Physiotherapy investigated gave the following result:

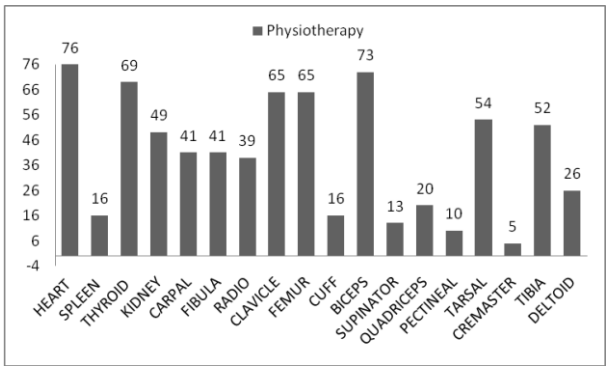

For the 136 nursing students surveyed gave the following result:

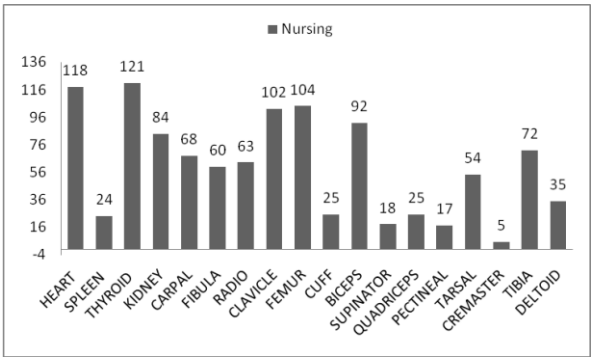

For 61 Physical Education students surveyed gave the following result:

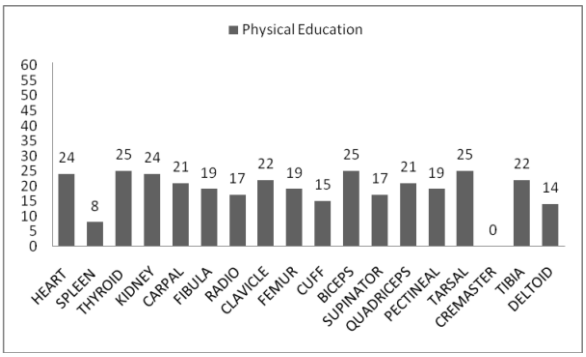

CONCLUSION

It is concluded that in relation to the knowledge of students from 1st to 4th periods of Veiga de Almeida University Campus Cabo Frio RJ, compared to classes and anatomical structures of classes of Physiotherapy, Nursing and Physical Education has the following percentage of correct answers for students of Physical Education: heart (39%), spleen (13%), thyroid (41%), kidney (39%), carpal bones (34%), fibula (31%), radio (28%), clavicle (36%); femur (31%); rotator cuff (25%); biceps brachial (41%); supinator (28%); quadriceps (34%); pectineal (31%); tarsal bones (41%); cremaster muscle (00%), tibia (36%), deltoid (23%), where all the structures were below 50% of hits. Nursing to the class have the following arrangements: heart (100%), spleen (21%), thyroid (93%), kidney (67%), the carpal bones (54%), the fibula (44%); radio (53%); clavicle (86%); femur (86%); rotator cuff (22%); biceps brachial (48%); supinator (18%); quadriceps (23%); pectineal (20%); tarsal bones (37%); cremaster muscle (00%), tibia (24%), deltoid (15%), where all the structures that were below 50 % of hits were spleen, fibula, rotator cuff, biceps, supinator, quadriceps, pectineus, tarsal bones, muscle cremaster, tibia and deltoid. Physiotherapy to the class have the following arrangements: heart (100%), spleen (21%), thyroid (91%), kidney (65%), the carpal bones (54%), the fibula (54%); radio (51%); clavicle (86%); femur (86%); rotator cuff (21%); biceps brachial (96%); supinator (17%); quadriceps (26%); pectineal (13%); tarsal bones (71%); cremaster muscle (07%), tibia (68%), deltoid (34%), where the following structures were below 50 % of hits: spleen, rotator cuff, supinator, quadriceps, pectineus, cremaster muscle and deltoid . It is concluded that the knowledge of students from 1st to 4th periods of Veiga de Almeida University Campus Cabo Frio RJ, compared to classes and anatomical structures of classes of Physiotherapy, Nursing and Physical Education is very low in relation to the following structures: spleen, rotator cuff, supinator, cremaster muscle, quadriceps, pectineus, fibula, biceps, tarsal bones, the tibia and deltoid.

REFERENCES

CORREDERA, B. M.; Santana, P. L. Relevancia de la anatomia humana en el ejercicio de la medicina de asistencia primaria y em el estudio de las asignaturas de segundo ciclo de la licenciatura en medicina. Educación médica, v. 6, n. 1, p. 41-51, 2003.

COSTA, A. P. Ensino da anatomia humana em cursos de graduação em educação física. 2007. 251 f. Dissertação (Mestrado em Educação Física) - Programa de pós-graduação Stricto Sensu - Universidade São Judas Tadeu, São Paulo, 2007.

DAMASCENO Sérgio Augusto Nader; Maria Aparecida Cória-Sabini. Ensinar e Aprender: Saberes e Práticas de Professores de Anatomia Humana. Rev. Psicopedagogia 2003; 20(63): 243-54.

DANGELO, J.G., Fattini, C.A. Anatomia Humana Sistêmica e Segmentar. 30 ed. Rio de Janeiro: Atheneu, 2007.

FORNAZIERO, Célia Cristina; Célia Regina Rodrigues Gil. Novas Tecnologias Aplicadas ao Ensino da Anatomia Humana. Revista Brasileira de Educação Médica. Rio de Janeiro, v. 27, nº 2, maio/ago. 2003

HORNE, D. J. et al. Rections of first-year medical students to their initial encounter with a cadaver in the dissecting room. Acd. Méd. v. 65, n. 10, p. 645-646, 1990.

JACOB, Stanley W. Francone, Clarice A. Lossow, Walter J. Anatomia e fisiologia humana. 5ª edição. São Paulo. Guanabara Koogan, 1990.

LEANDRO Nobeschi. Instituto de Imagem em Saúde – CIMAS. 10/9/2010 Introdução ao Estudo da Anatomia Humana.

McLACHLAN, John C.; Patten, Debra. Anatomy teaching: ghosts of the past, present and future. Medical Education, mar. 2006, V. 40. Disponível em: <http://www.mededuc.com>. Acesso em: 28 jan. 2013.

MADEIRA, M. C. Sou professor universitário e agora? Manual de primeira leitura do professor. São Paulo: Sarvier, 2008. 156 p.

MIRANDA, Edalton. Bases de Anatomia e Cinesiologia. Rio de Janeiro, editora Sprint, 2000.

PASCARELLA, E. T., & Terenzini, E. T. (2005). How college affects students: A third decade of research. (Vol. 2). San

Francisco: Jossey-Bass.

PERREIRA, José. A. et all. Effectiveness of using blended learning strategies for teaching and learning human anatomy. Medical Education, 2007, V. 41. Disponível em: <http://www.mededuc.com>. Acesso em: 28 jan. 2013.

PIATTO, V. B.; Batigália, F. Utilização de peças anatômicas de cadáver e o ensino médico. HB Científica, v. 7, n. 2, maio/ago. 2000.

PIAZZA Bruno Luis; Attico Inácio Chassot. Anatomia Humana, uma disciplina que causa evasão e exclusão: quando a hipótese principal não se confirma. Revista Ciência em Movimento | Ano XIV | Nº 28 | 2012.

STACCIARINI, J. M. R.; Esperidião, E. Reviewing teaching strategies in a learning process. Rev. Latino-am. Enferm. v. 7, n. 5, 1999.

REASON, R. D., Terenzini, P. T., & Domingo, R. J. (2006). First things first: Developing academic competence in the first year of college. Research in Higher Education, 47, 149-175.

SILVA, R. A.; Guimarães, M. M. Arte educação: facilitando o ensino de morfologia. Educere, v. 4, n. 1, p. 55-63, 2004.

Rodovia RJ 140 – Km 05 – Condomínio Residencial Olga Diuana Zacharias.
Rua Dos Crisântemos, nº 37 – lote 38 – quadra 08 – Campo Redondo –
São Pedro D´Aldeia – RJ – CEP: 28940000 – Brasil.
jau.f.cruz@hotmail.com

KNOWLEDGE OF STUDENTS OF 1 TO 4 TIMES ON THE ANATOMY AND SYSTEMIC LOCOMOTOR, UNIVERSITY IN CABO FRIO VEIGA DE ALMEIDA, RJ.

ABSTRACT

We conclude that with the questions related to the following structures: heart, spleen, thyroid, kidney, carpal bones, fibula, radio, clavicle, femur, rotator cuff, biceps, supinator, quadriceps, pectineus, tarsal bones, cremaster muscle, tibia and deltoid, where 273 students were investigated of the morning and evening: 76 students of Physiotherapy; 136 students of Nursing and 61 students of Physical Education concluded that for these classes has the following percentage of success for students of Physical Education : heart (39%), spleen (13%), thyroid (41%), kidney (39%), carpal bones (34%), fibula (31%), radio (28%); clavicle (36%); femur (31%); rotator cuff (25%); biceps brachial (41%); supinator (28%); quadriceps (34%); pectineal (31%); tarsal bones (41%); cremaster muscle (00%), tibia (36%), deltoid (23%), where all the structures were below 50% of hits. Nursing to the class have the following arrangements: heart (100%), spleen (21%), thyroid (93%), kidney (67%), the carpal bones (54%), the fibula (44%); radio (53%); clavicle (86%); femur (86%); rotator cuff (22%); biceps brachial (48%); supinator (18%); quadriceps (23%); pectineal (20%); tarsal bones (37%); cremaster muscle (00%), tibia (24%), deltoid (15%), where all the structures that were below 50 % of hits were spleen, fibula, rotator cuff, biceps, supinator, quadriceps, pectineus, tarsal bones, cremaster muscle, tibia and deltoid. Physiotherapy to the class have the following arrangements: heart (100%), spleen (21%), thyroid (91%), kidney (65%), the carpal bones (54%), the fibula (54%); radio (51%); clavicle (86%); femur (86%); rotator cuff (21%); biceps brachial (96%); supinator (17%); quadriceps (26%); pectineal (13%); tarsal bones (71%); cremaster muscle (07%), tibia (68%), deltoid (34%), where the following structures were below 50 % of hits: spleen, rotator cuff, supinator, quadriceps, pectineus, cremaster muscle and deltoid. It was concluded that in relation to classes and anatomical structures of classes of Physiotherapy, Nursing and Physical Education is very low in relation to the following structures: spleen, rotator cuff, supinator, cremaster muscle, quadriceps, pectineus, fibula, biceps, bones tarsus, tibia and deltoid.

KEYWORDS: Anatomy, higher education, human body.

CONNAISSANCES DES ÉLÈVES DE 1 À 4 FOIS SUR L'ANATOMIE ET DE LA LOCOMOTION SYSTÉMIQUES, NA UNIVERSITÉ VEIGA DE ALMEIDA CABO FRIO, RJ.

RÉSUMÉ

Nous concluons que les questions relatives aux ouvrages suivants: coeur, la rate, la thyroïde, les reins, les os du carpe, du péroné, de la radio, de la clavicule, du fémur, la coiffe des rotateurs, biceps, supinateur, les quadriceps, pectiné, les os du tarse, cremaster musculaires, le tibia et le deltoïde, où 273 élèves ont été étudiés du matin et du soir: 76 étudiants de physiothérapie; 136 étudiants de sciences infirmières et 61 étudiants en éducation physique ont conclu que pour ces classes a le pourcentage suivant de la réussite des élèves de l'éducation physique: coeur (39%), de la rate (13%), de la thyroïde (41%), les reins (39%), les os du carpe (34%), le péroné (31%), la radio (28%); clavicule (36%); fémur (31%); la coiffe des rotateurs (25%); biceps brachial (41%); supinateur (28%); quadriceps (34%); pectiné (31%); os du tarse (41%); cremaster musculaires (00 %), le tibia (36%), la région deltoïde (23%), où toutes les structures étaient en dessous de 50 % des hits. Soins infirmiers à la classe ont les dispositions suivantes: coeur (100%), de la rate (21%), de la thyroïde (93%), les reins (67%), les os du carpe (54%), la fibula (44%); Radio (53%); clavicule (86%); fémur (86%); la coiffe des rotateurs (22%); biceps brachial (48%); supinateur (18%); quadriceps (23%); pectinés (20%); os du tarse (37%); cremaster musculaires (00%), le tibia (24%), la région deltoïde (15%), où toutes les structures qui étaient en dessous de 50 % des hits étaient rate, péroné, coiffe des rotateurs, biceps, supinateur, quadriceps, pectiné, les os du tarse, cremaster musculaires, le tibia et le deltoïde. Physiothérapie à la classe ont les dispositions suivantes: coeur (100%), de la rate (21%), de la thyroïde (91%), les reins (65%), les os du carpe (54%), la fibula (54%); Radio (51%); clavicule (86%); fémur (86%); la coiffe des rotateurs (21%); biceps brachial (96%); supinateur (17%); quadriceps (26%); pectinés (13%); os du tarse (71%); cremaster musculaires (07%), le tibia (68%), la région deltoïde (34%), où les structures suivantes étaient moins de 50% des hits: rate, coiffe des rotateurs, supinateur, quadriceps, pectiné, cremaster musculaire et deltoïde. Il a été conclu que par rapport à des classes et des structures anatomiques de classes de physiothérapie, soins infirmiers et de l'éducation physique est très faible par rapport aux structures suivantes: la rate, coiffe des rotateurs, supinateur, cremaster musculaires, les quadriceps, pectiné, le péroné, les biceps, les os tarse, le tibia et le deltoïde.

MOTS-CLÉS: anatomie, l'enseignement supérieur, le corps humain.

CONOCIMIENTO DE LOS ALUMNOS DE 1 A 4 VECES EN LA ANATOMÍA DEL APARATO LOCOMOTOR SISTÉMICO, NA UNIVERSIDAD VEIGA DE ALMEIDA CABO FRIO, RJ.

RESUMEN

Llegamos a la conclusión de que las cuestiones relacionadas con las siguientes estructuras: corazón, bazo, tiroides, riñón, huesos del carpo, peroné, radio, clavícula, fémur, manguito rotador, bíceps, supinador, cuádriceps, pectíneo, los huesos del tarso, el músculo cremáster, la tibia y el músculo deltoides, donde 273 estudiantes fueron investigados de la mañana y la tarde de 76 estudiantes de Fisioterapia, 136 estudiantes de enfermería y 61 estudiantes de Educación Física concluyó que para estas clases tiene el siguiente porcentaje de éxito de los estudiantes de Educación Física: corazón (39 %), bazo (13 %), tiroides

(41 %), riñón (39%), los huesos del carpo (34 %), el peroné (31 %), la radio (28 %); clavícula (36 %); fémur (31 %); manguito de los rotadores (25 %); bíceps braquial (41 %); supinador (28%); cuádriceps (34 %); pectineal (31 %); huesos del tarso (41 %); músculo cremáster (00 %), la tibia (36 %), deltoides (23 %), donde todas las estructuras estaban por debajo de 50 % de los accesos . Enfermería de la clase tiene el siguiente régimen : corazón (100%), bazo (21 %), tiroides (93 %), riñón (67 %), los huesos del carpo (54 %), el peroné (44%); Radio (53 %); clavícula (86 %); fémur (86 %); manguito de los rotadores (22 %); bíceps braquial (48 %); supinador (18 %); cuádriceps (23 %); pectíneos (20 %); huesos del tarso (37 %); cremáster musculares (00 %), la tibia (24 %), deltoides (15 %), donde todas las estructuras que estaban por debajo de 50 % de los accesos fueron el bazo, el peroné, manguito de los rotadores, bíceps, supinador, cuádriceps, pectíneo, los huesos del tarso, el músculo cremáster, la tibia y el músculo deltoides Fisioterapia para la clase tiene el siguiente régimen: corazón (100 %), bazo (21 %), tiroides (91 %), riñón (65 %), los huesos del carpo (54 %), el peroné (54 %); Radio (51 %); clavícula (86 %); fémur (8 %); manguito de los rotadores (21 %); bíceps braquial (96 %); supinador (17 %); cuádriceps (26%); pectíneos (13 %); huesos del tarso (71 %), músculo cremáster (07 %), la tibia (68%), deltoides (34 %), en las siguientes estructuras estaban por debajo del 50 % de los accesos: el bazo, el manguito de los rotadores, supinador, cuádriceps, pectineus, músculo cremáster y deltoides. Se concluyó que en relación con las clases y las estructuras anatómicas de las clases de Fisioterapia, Enfermería y Educación Física es muy bajo en relación con las siguientes estructuras: el bazo, el manguito de los rotadores, supinador, músculo cremáster, cuádriceps, pectíneo, peroné, bíceps, los huesos tarso, la tibia y el deltoides.

PALABRAS CLAVE: anatomía, la educación superior, el cuerpo humano.

O CONHECIMENTO DE ALUNOS DO 1º AO 4º PERÍODOS EM RELAÇÃO À ANATOMIA SISTÊMICA E LOCOMOTORA, NA UNIVERSIDADE VEIGA DE ALMEIDA CABO FRIO, RJ.

RESUMO

Conclui-se que com as perguntas relacionadas às seguintes estruturas: coração, baço, tireoide, rim, ossos do carpo, fíbula, rádio, clavícula, fêmur, manguito rotador, bíceps braquial, supinador, quadríceps, pectíneo, ossos do tarso, músculo cremáster, tíbia e deltoide, onde foram investigados 273 alunos dos períodos da manhã e noite: 76 alunos do curso de Fisioterapia; 136 alunos do curso de Enfermagem e 61 alunos do curso de Educação Física concluiu-se que em relação a estas turmas tem-se o seguinte percentual de acertos para os alunos do curso de Educação Física: coração (39%); baço (13%); tireóide (41%); rim (39%); ossos do carpo (34%); fíbula (31%); rádio (28%); clavícula (36%); fêmur (31%); manguito rotador (25%); bíceps braquial (41%); supinador (28%); quadríceps (34%); pectíneo (31%); ossos do tarso (41%); músculo cremáster (00%); tíbia (36%); deltóide (23%), onde todas as estruturas ficaram abaixo de 50% dos acertos. Para a turma de Enfermagem têm-se os seguintes acertos: coração (100%); baço (21%); tireóide (93%); rim (67%); ossos do carpo (54%); fíbula (44%); rádio (53%); clavícula (86%); fêmur (86%); manguito rotador (22%); bíceps braquial (48%); supinador (18%); quadríceps (23%); pectíneo (20%); ossos do tarso (37%); músculo cremáster (00%); tíbia (24%); deltóide (15%), onde todas as estruturas que ficaram abaixo de 50% dos acertos foram baço, fíbula, manguito rotador, bíceps braquial, supinador, quadríceps, pectíneo, ossos do tarso, músculo cremáster, tíbia e deltóide. Para a turma de Fisioterapia têm-se os seguintes acertos: coração (100%); baço (21%); tireóide (91%); rim (65%); ossos do carpo (54%); fíbula (54%); rádio (51%); clavícula (86%); fêmur (86%); manguito rotador (21%); bíceps braquial (96%); supinador (17%); quadríceps (26%); pectíneo (13%); ossos do tarso (71%); músculo cremáster (7%); tíbia (68%); deltóide (34%), onde as seguintes estruturas ficaram abaixo de 50% dos acertos: baço, manguito rotador, supinador, quadríceps, pectíneo, músculo cremáster e deltoide. Conclui-se então que em relação às aulas e estruturas anatômicas das turmas de Fisioterapia, Enfermagem e Educação física é muito baixo em relação as seguintes estruturas: baço, manguito rotador, supinador, músculo cremáster, quadríceps, pectíneo, fíbula, bíceps braquial, ossos do tarso, tíbia e deltóide.

PALAVRAS-CHAVES: Anatomia, ensino superior, corpo humano.