06 - INFANTILE ANTROCHOANAL POLIP: EDUCATIONAL AND SOCIAL ASPECTS

RACHEL SCHLINDWEIN - ZANINI[1]; FÁBIO D. ZANINI[2]; GECIELY ALMEIDA[3]
Neuropsicóloga; Doutora em Neurociências, pela Faculdade de Medicina da Pontifícia Universidade Católica do Rio Grande do Sul PUCRS. Pós-doutoranda em Psicologia pela Universidade Federal de Santa Catarina - UFSC. Florianópolis/SC. E-mail:
[2] Otorrinolaringologista; Mestrando em Otorrinolaringologia, pela Santa Casa de Misericórdia de São Paulo.
[3] Fisioterapeuta; Especialista em Desenvolvimento Infantil, Mestre em Ciências do Movimento Humano, pela Universidade do Estado de Santa Catarina - UDESC.
Florianópolis, SC / Brasil.
rachelsz@floripa.com.br

INTRODUCTION

Nowadays, innumerous otorhinolaryngological diseases might interfere in the social and educational life of children, among them the antrochoanal polyp (or polyp of Killian), an isolated benign polyploidy injury, that is observed mainly children and young adults. Researches have shown that this polyp represents around 4-6% of all nasal polyps among the whole population. However, within the pediatric population, this percentage reaches 33%. In the most advanced cases, it can affect the psychological, educational and social development of the child and the pediatric patients. The quality of life of the child might be compromised. Ravens-Sieberer (2006) states that the quality of life must be analyzed according to the age and the stage of the development of the child, and these investigations of the quality of life of the children might contribute in the evaluation of the control of the necessities, in the decision making and of quality in the health care.

Although this is not a rare disease, the polyp of Killian, had not been mentioned within the last years, with very few published cases in the specialized literature (Freitas e cols, 2006).

OBJECTIVE

The objective of this case research is the investigation of the interference in the diagnosis of "antrochoanal polyp" (PA) in the educational and social aspects of the student.

METHODOLOGY AND RESULTS

Case research: Patient V.P., female, 5 years old, diagnosed with antrochoanal polyp (PA), who was seen in a Hospital Institution (Florianópolis, SC, Brazil) diagnosed with obstruction of an important superior aerial respiratory tract which is associated to the polyploidy injury externalizing previously in the left nostril, according to the pictures 1 and 2.



Picture 1

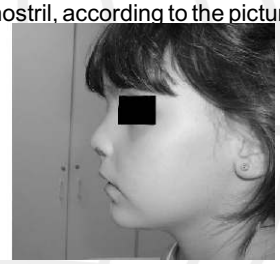

Picture 2

According to the research of Freitas et al (2006), which investigated 16 cases of PA, most of the polyps (62,5%) were located in the left nostril, confirming the presented case. The majority of the occurrences related to the period of development is the childhood, which also confirms the data.

Complementary exams: A computer axial tomography (TAC) was made in the para nasal cavities which have shown an extended tumor mass from the very beginning of the left nostril to the rhinopharynx. In a suspicion of PA, a nasal sinus surgery was made, with a complete withdrawn of the injury that was located in the maxillary. The anatomy pathologycal exam confirmed the diagnosis of PA and the patient developed healed, without recidivism.

Psychological evaluation: Besides the psychological, educational and social aspects, other aspects were involved within the realization of the anamnesis, projective tests were applied (HTP) and the "Scale of Children's Quality of Life" (Autoquestionnaire Qualité de Vie Enfant Imagé -AUQEI), in Barreire et al (2003). After the appearing of the PA, the patient presented psychological changes such as excitement, irritability and anxiety, quirks (oral) and tensional cephalic, sociability restrictions, feelings of inferiority, protection desire, bare contact with the reality and being easily influenced. It was seen sleeping disorders, such as waking up easily and scared. (Started by the PA).

So, Ravens-Sieberer (2006) explains that the quality of life should be examined in relation to the age and the stage of child's development.

Motor Evaluation: The motor evaluation of the child was normal. The dynamic observation of the motor behavior throughout specific tests is part of a variety of researches made by classic authors, such as Ozeretsky, Guilmain, Zazzo, Piaget, Stambak, Vayer and other ones. Many essays have been related to the early detection of different deviations of human life. An appropriate motor control promotes the exploration of the environment from concrete experiences, which will subsidy the intellectual development of the child (Rosa Neto, 2002).

Social and School issues: About the school, the child attends the pre-elementary school with a normal performance. According to the patient and her mother, when the polyp was seen by her classmates, it provoked laughs and jokes from them to the patient, preventing her from a normal social development and relationship, and making her believe that these interpersonal relations were unpleasant and leading her to isolation. The group activities were reduced.

Amiralian (1986) complements: "In a more advanced level, the discrimination is transformed into a real segregation or isolation, in the primary group (family, school), or in the social activities." The social competence, extended as a concept to designate the capacity of interaction and adaptation of the child to the group is jeopardized (Attili, 1990). A model for explaining

the consequences of this lack of social competence was proposed by Furnham (1989). It seems to install a routine which is really hard to be changed without exterior help (Picture 3). Social competence deficits result in lack of friends and social isolation that can arise different kinds of reactions.

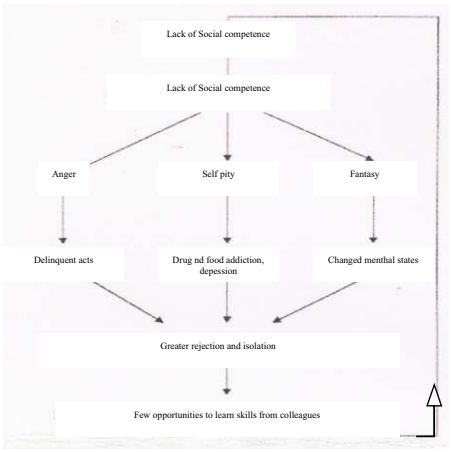

PICTURE 3.

The Physical Education and Physiotherapy have been highlighted as pedagogical-therapist conduct, effective in the accompaniment of diseases of the respiratory system. Injuries of the thorax, respiratory conducts, lung parenchyma and muscular system have been satisfactory responding to the application of kinesiology concept, manual and educational used in this area.

These professionals are no longer limited to their working environment, but inserted in multi-professional teams inside the clinics, hospitals, health center and schools. The basic principle that leads the work of these professionals is the individual adaptation to a social and labored life, compatible to the respiratory dysfunction degree.

The professionals who work with children who suffer from respiratory diseases - including the physical education professional - must have a minimal knowledge about the impact f these diseases on the global development of the child, which evolves information about etiology and the effects of the medication until they take care of the crisis cases or problems caused by the disease. Regarding the use of medication (painkillers and antinflaming), Becker et al (2003) with the objective of analyzing the risk of using painkillers and antinflaming in patients who were tolerant or non tolerant to aspirin, it was seen , investigating 45 patients (Among them - 15 with polyp who were tolerant to aspirin, 15 with polyp who were intolerant to aspirin and 15 control group), that the bronchi spasm was the main reaction to the aspirin, this diagnosis must be as brief and precise as possible, in order to avoid bigger complications, as the bronchi spasm can lead to the known breathless sensation. The Physical Education professional must be aware of it and alert both parents and teachers about the need of this diagnosis and early treatment.

According to Mozzer and Laizo (2006) “The practice of light and controlled exercises increases the cardio-respiratory and it takes the patient to an improvement”. The knowledge of physiology of the bronchi spasm, as well as the pharmacology therapy used to invert the situation, represents an important tool for the physical educator and the physiotherapist, that is necessary to the elaboration of a rehabilitation program, allowing that the injury is successfully healed, in a shorter time, taking the patient back to its normal life as early as possible.

On the surgery occurrences, which very often causes the isolation of the child from its regular social and educational environment, Abritta et al (2004) studying 30 patients who were submitted to a endonasal micro-surgery, found 40% frequency of recidivism, more common in the boys. However, 60% of the patients were freed from the recidivism, showing that the surgery can be effective in the total resolution of the problem, minimizing the chances of isolating the child.

So, it is seen that the process of integration/ sociabilization, assimilation, illness/ recovering, trauma overcoming and difficulties to learn, of those who suffer from respiratory problems evolves both the health team (as the psychologist, doctor, physiotherapist and nurse), but also professionals of other areas, as he educator (Schlindwein - Zanini e Almeida, 2007).

CONCLUSION

The antrochoanal polyp (PA) has physical and social repercussions, and it might interfere in the social, educational and quality life of the child. The intervention of the educator is necessary focusing on a better inclusion of the individual who suffers from PA in the school.

Finally, the research has shown that the PA generates difficulties in the social and educational life of the child, beside its quality of life.

The educator has an important role, as he/she is the link among the child, the school and the colleagues, and it might act in the social interaction and in the self-esteem of this individual.

So, the evaluation and intervention of the educator is necessary too, focusing on a better inclusion and adaptation of this individual in the school.

REFERêNCIAS BIBLIOGRáFICAS

AMIRALIAN, M. L. **Psicologia do excepcional**. São Paulo: EPU; 1986.

BARREIRE, S. G. et al. Qualidade de vida de crianças ostomizadas na ótica das crianças e das mães. **J Pediatria.** vol 79, n 1. 2003.

CHAN, K. H. et al. Pediatric otolaryngology: a psychosocial perspective. **Int J Pediatr Otorhinolaryngol.** May; 32 (2):159-66. 1995.

CAMPOS, D. **O teste do desenho como instrumento de diagnóstico da personalidade**. Petrópolis: Vozes. 1990.

FREITAS, M. R. et al. Pólipo antrocoanal: uma revisão de dezesseis casos. **Rev Bras Otorrino.** 2006 - 72(6):831-35.

FURNHAM, A. Friendship and personal development. R. Porter & S. Tomaselli (Org.) - **The dialectics of friendship**. 1989 (92-110). London: Routledge.

RAVENS-SIEBER, U. Special aspects of the quality of life of children. **Dtsch Med Wochenschr**. May 12;131(19 Suppl 1):S27-30. 2006.

ROSA NETO, F. **Manual de avaliação motora.** Porto Alegre: Artmed, 2002.
SCHLINDWEIN - ZANINI, R; ALMEIDA, GMF. Cystic Fibrosis and psychological aspects: case report. **Journal of the International Federation of Phisical Education** (**FIEP Bulletin)**. v 77. special edition. Article I. p. 605 - 608. 2007.
STAMM, A. C. **Microcirurgia naso-sinusal**. Rio de Janeiro: Revinter. 1995.
ABRITTA, D; CORACARI AR; MANIGLIA, JV. Microcirurgia na polipose nasal: análise evolutiva clínica e cirúrgica. **Rev. Bras. Otorrinolaringol.**, mar./abr. vol.70, no.2, p.156-162. 2004.
BECKER, HMG; NASCIMENTO, E; GUIMARAES, RES et al. Uso de analgésicos e antiinflamatórios em pacientes portadores de polipose nasossinusal eosinofílica tolerantes e intolerantes à aspirina. **Rev. Bras. Otorrinolaringol.**, maio/jun. vol.69, no.3, p.296-302. 2003.
MOZER, DD; LAIZO, A. **A crise do broncoespasmo**. Fisioweb. Disponível em: <www.fisioweb.com.br>. Acesso: abril, 2006.

Rachel Schlindwein - Zanini.
e-mail: rachelsz@floripa.com.br
Rua: Lauro Linhares, 2123, torre 1, sala 612. cep: 88036-002.
Bairro: Trindade. Florianópolis / SC. Brasil.

INFANTILE ANTROCHOANAL POLIP: EDUCATIONAL AND SOCIAL ASPECTS

ABSTRACT

Currently the frequency of the otorhinolaryngological diseases is increasing that they can intervene with the social and educational life of a child. Among them the antrochoanal polyp, in its more advanced cases can shake the psychological, educational and social development of the pediatrics patients. The objective of this work is to analyze and to alert concerning the educational and social aspects that this illness can unchain. Patient V.P. of the feminine sex, 5 years of age, with diagnosis of antrochoanal polyp, with obstruction of important superior airway associated the polyp injury extruding previously in nasal cavity left, submitted the surgery and the psychological evaluation. This consisted of anamneses, application of the projective test (HTP) and of the "Child Scale of Quality of Life" (Auto questionnaire Qualité de Vie Enfant Imagé - AUQEI) that they had detached that after the sprouting of the antrochoanal polyp, the patient presented psychological alterations and worsening of the quality of life. Thus, the present work also showed that the antrochoanal polyp has to bring disorders in the social and educational scope, also in the quality of life of the child, where the intervention of the educator is necessary, aiming at the best inclusion and adaptation of this individual in the school. KEY-WORDS: Child, antrochoanal polyp, social aspects, educational aspects

POLYPE ANTROCHOANAL: ASPECTS ÉDUCATIFS ET SOCIAUX

RÉSUMÉ

Actuellement la fréquence des maladies otorhinolaryngologique augmente qu'ils peuvent intervenir avec la vie sociale et éducative d'un enfant. Entre eux le polype antrochoanal dans ses cas plus avançés peut secouer le développement psychologique, éducatif et social des patients de pédiatrie. L'objectif de ce travail est analyser et alerter au sujet des aspects éducatifs et sociaux que cette maladie peut désenchaîner. Le patient V.P. du sexe féminin, 5 ans, avec le diagnostic du polype antrochoanal, avec l'obstruction de la voie aérienne supérieure importante a associé les dommages de polip expulsant précédemment en cavité nasale à gauche, soumis la chirurgie et l'évaluation psychologique. Cet anamnese composé, application de l'essai projectif (HTP) et de balance d'enfant de la qualité de la vie" (Autoquestionnaire Qualité de Vie Enfant Imagé - AUQEI) cette elles avaient détaché cela après la germination du polip d'antrochoanal, le patient présent des changements et la détérioration psychologiques de la qualité de la vie. Ainsi, le travail actuel a également prouvé que le polip d'antrochoanal doit apporter des désordres dans la portée sociale et éducative, aussi de la qualité de la vie de l'enfant, où l'intervention de l'éducateur est nécessaire, visant la meilleures inclusion et adaptation de cet individu dans l'école.

MOTS CLÉS: Enfant, Polype antrochoanal, aspects sociaux, aspects éducatifs.

PÓLIPO ANTROCOANAL: ASPECTOS EDUCATIVOS Y SOCIALES

RESUMEN

Actualmente es aumentada la frecuencia de las enfermedades otorrinolaringologicas que pueden intervenir con la vida social y educativa de un niño. Entre ellas el pólipo antrocoanal, en sus casos más avanzados puede sacudarir el desarrollo psicologico, educativo y social de los pacientes de la pediatría. El objetivo de este trabajo es analizar y alertar referente a los aspectos educativos y sociales de la enfermedad puede mostrar. El paciente V.P. del sexo femenino, 5 años de la edad, con la diagnosis del pólipo antrocoanal, con la obstrucción de la vía aérea superior importante asoció lesión del polip que se extiende a lo exterir previamente en cavidad nasal a la izquierda, sometida la cirugía y la evaluación psicologica. Esta evaluación consiste en anamnese, uso de la prueba descriptiva (HTP) y de la "escala de la calidad de la vida del niño" (Autoquestionnaire Qualité de Vie Enfant Imagé - AUQEI) esa habían separado eso después de brotar pólipo antrocoanal, el paciente presentado alteraciones psicológicas y el empeoramiento de la calidad de la vida. Así, el actual trabajo también demostró que el polip del antrochoanal tiene que traer desórdenes en el alcance social y educativo, también en la calidad de la vida del niño, donde está necesaria también, la intervención del educador, teniendo como objetivo la mejores inclusión y adaptación de este individuo en la escuela.

PALABRAS CLAVES: Niño, Pólipo antrocoanal, aspectos sociales, aspectos educativos.

PóLIPO ANTROCOANAL INFANTIL: ASPECTOS EDUCACIONAIS E SOCIAIS

RESUMO

Atualmente é crescente a freqüência das afecções otorrinolaringológicas, que podem interferir na vida social e educacional de uma criança. Entre elas o pólipo antrocoanal (PA), em seus casos mais avançados pode abalar o desenvolvimento psicológico, educacional e social dos pacientes pediátricos. O objetivo deste trabalho é analisar e alertar acerca dos aspectos educacionais e sociais que esta doença pode mostrar. Paciente V.P. do sexo feminino, 5 anos de idade, com diagnóstico de pólipo antrocoanal (PA), com quadro obstrutivo de via aérea superior importante, associado a lesão polipóide exteriorizando-se anteriormente na fossa nasal esquerda, submetida a cirurgia e a avaliação psicológica. Esta consistiu em anamnese, aplicação da testagem projetiva (HTP) e da "Escala de Qualidade de Vida da Criança" (Autoquestionnaire Qualité de Vie Enfant Imagé -AUQEI) que destacaram que após o surgimento do PA, a paciente apresentou alterações psicológicas, sociais e educacionais e piora da qualidade de vida. Conclui-se que o PA pode trazer comprometimentos no âmbito social e educacional, inclusive na qualidade de vida da criança, onde a intervenção do educador é necessária visando a melhor inclusão e adaptação deste indivíduo na escola.

PALAVRAS-CHAVE: Criança, Pólipo antrocoanal, aspectos sociais, aspectos educacionais.