35 - USE OF THE THERAPEUTIC ULTRASOUND AND LASER THERAPY IN THE INITIAL FORMATION OF BONE CALLUS

FABRÍCIO BORGES OLIVEIRA[1,2], SÉRGIO CARDOSO BARCELOS[1,2], ALINE ELIETE DE AGUIAR[2] E CÉLIO DONIZETE FERREIRA[3]

INTRODUCTION

Actually we found a variety of interventions proposed in the intention of minimizing the retard of the consolidations of fractures and pseudoartrosis, however, without great results. With promising results they have if outstanding the several physical resources, among them, the use of the ultrasound of low intensity, the therapeutic ultrasound and the radiation with laserterapia of low intensity, employees with great frequency for physiotherapists in the aid and treatment of dysfunctions of the biological fabrics, according to Lewin and Ziskin (1993) and Lirani (2004).

Some experimental models have been accomplished, presenting as objective the understanding of the development mechanism and adaptation of the bone fabric in the phase of consolidation of fractures, and the alterations that happen in relation to the properties biomechanics after a certain immobilization period; investigating the effects of UST, as well as, the application of the Laser of low intensity in the cellular activity (CHANG *et al.*, 2000; HECKMAN & SARASOHN, 2000; LIRANI, 2004).

UST has been used since the decade of 1950, and to the end of that decade, Fukada and Yasuda (1957) they verified the effects piezoelectric produced the bone fabric close to after the stimulation, making possible the performance front to the repairing process in fractures.

UST and TLBI have been studied front thoroughly the treatment of several conditions, as the repair and remodelation of lesions in woven soft and bone, having presented significant results, however, the studies use parameters and duration of very different treatment, because specific determinations of dosimeter and action mechanism don't exist for different cellular types, hindering the comparison of the meson (COOMBLE *et al.*, 2001).

The consolidation of the fractures happens with the formation of the call fracture callus. He is defined as the group of fabrics reparative that you/they are formed in a focus of the skeleton, in the measure in that he/she settles down a continuity solution in the bone. The callus of the fracture has for purpose re-stabile the integrity, the continuity and the rigidity of the bone piece, allowing the return to his/her function.

With base in effective scientific results, we investigated in this study the effects of the application of the therapeutic ultrasound (UST) of 1 MHz and application of the irradiation of the LASER (Aluminum-Gálio-Indian-match - AlGaInP), in the initial formation of bone callus in the shinbone of female rats when associates to the spica cast immobilization.

METHODOLOGY

The sample was constituted by seventeen albino female rats, of the lineage Wistar, with medium corporal weight of 380 grams, supplied by Biotery of the Academical Center of the Plateau of Araxá - UNIARAXÁ. These animals were separate and maintained in contention cage, with the maximum number of three animals for cage, with free access to the water and ration, being exposed at cycles of twelve hours clearing and twelve hours darkness until the production of the experimental lesion.

This study was approved by the Committee of Ethics and Research of UNIARAXÁ, being in accordance with norms and ethical beginnings of research in animals through the Resolution 196/96, Law no. 6.638, of May 8, 1979 and I Decree no. 24.645, of July 10, 1934.

All the animals were heavy and identified in agreement with the experimental group, being divided in three experimental groups in agreement with the treatment protocol:

GROUP 1 - STIMULATION WITH UST (N=06): The animals of this group suffered experimental trauma through manual pressure in the 1/3 distal of the right shinbone, being immobilized immediately after the experimental fracture with spica cast, with the articulations of the hip, knee and right ankle in extension. It was made at the place of the fracture an access window for the ultrasonic stimulation as intervention form in the process of bone consolidation. These animals stayed in their contention cages for fifteen days to the day of the sacrifice.

In this group 1 the apparel of the mark was used Bioset, I model Sonacel III, with presence of it was of 3,5 cm^2 adapted to the coupler, frequently of 1 MHz, cycle of work of 50%, intensity 0,5 W/cm^2. Fourteen sessions of three minutes were accomplished each, after 24 hours powders trauma, once a day, in a consecutive way.

GROUP 2 - STIMULATION WITH LASER AlGaInP (N=06): The animals of this group suffered the same process of experimental trauma and, following by the same protocol of immobilization of the group 1. It was Also made at the place of the fracture an access window for the radiation stimulation to Laser

In this group the fractured member was treated with therapeutic laser of low intensity AlGaInP, of the mark KW, infra-red bunch, with wavelength 904 nm, 30 potency mW and dose of 4 J/cm2, punctual application, for 12 seconds, in 14 sessions after 24 hours powders trauma, consisting of a daily application consecutively for fourteen days.

GROUP 3 - it CONTROLS (N=05): The animals of this group suffered the same procedure for accomplishment of the experimental fracture, being later to the trauma immobilized with the spica cast however without the access window during fifteen days to the day of the sacrifice.

For the accomplishment of the experimental lesion all the animals were previously anesthetized with Thiopental® (Sodic Thiopental), in the dose of 4mg/100g, administered through intraperitoneal, being later accomplished the tricotomia of the whole area previous of the right shinbone.

The experimental lesion was produced through manual pressure, in the medium third of the right shinbone of each one of the animals being in accordance with studies of Castro *et al.* (2005); Giordano *et al.* (2001) and Santos *et al.* (1993).

PROTOCOL OF IMMOBILIZATION

The animals were immobilized manually and positioned in ventral decubitus with the lame-femoral articulation in extension being been the careful in maintaining the maximum extension of the knee and the articulation of the ankle traction, it fastens and positioned in flexing to plant. The model adopted for this study was based in a proposed by Booth and Kelso (2003), however adapted and used in this study only for one of the members as described by Matheus *et al.* (2008).

The immobilization was accomplished after the traction in the place of the fracture, through an spica cast that included from the thoracic area, including right inferior member, pelve, hip and knee, in total extension; the articulation of the ankle was

also included inside of the apparel, staying fastens and positioned in flexing to plant.

For the appropriate ultrasonic stimulation and TLBI a window of rectangular access was 4,0 cm^2 to the place of the fracture in the spica cast.

RESULTS

All of the interpretations of the exams accomplished radiologic were analyzed directly with a doctor orthopedic specialist for better validation and understanding of the discoveries.

The analysis radiographic accomplished in the group control didn't show satisfactory qualitative results related the formation of bone callus, because in none of the analyzed cases there were signs of bone consolidation, it only observed the fracture in 1/3 medium diafises of the shinbone of the transverse type with deviation in l pierce (Picture 1).

In the group treaty with UST, we just found a case at the beginning of formation of bone callus, as we can observe in the Picture 2, image 01.

There were important differences observed in the group treaty with TLBI in the analysis radiographic of the groups control and UST. In the group that received stimulation LASER 05 cases they were observed at the beginning of formation of bone callus (Picture 3, images 01, 02, 03, 04 and 06).

PICTURE 1 - Analysis radiographic of the group controls after 15 days of spica cast immobilization, evidencing fracture in third medium diafises of the shinbone of the transverse type with deviation in l pierce.

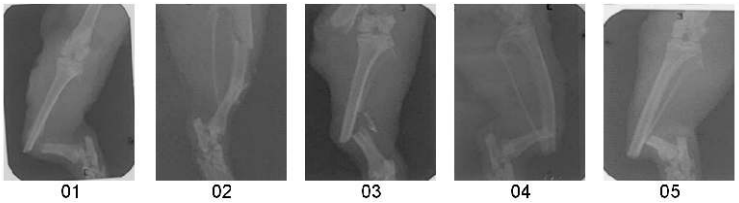

PICTURE 2 - Analysis radiographic of the group UST after 15 days of spica cast immobilization, indicating formation of bone callus in the focus of fracture of the image 01.

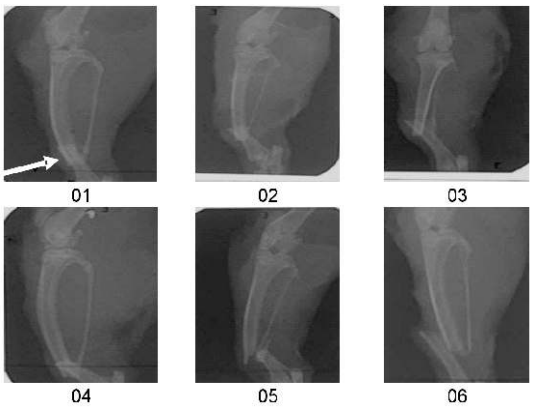

PICTURE 3 - Analysis radiographic of the group LASER after 15 days of spica cast immobilization, evidencing formation of bone callus in the images 01,02,03,04 and 06).

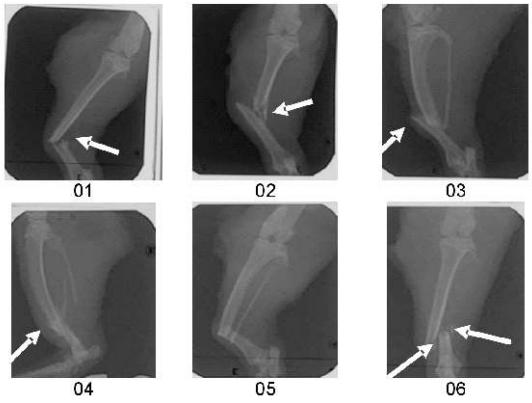

DISCUSSION

In this study the effects of UST were compared and of the laser of low intensity associated to the spica cast immobilization through experimental groups and control, being appraised results qualitative front to the initial formation of bone callus. The x-rays were analyzed and they presented significant differences in the process of formation of bone callus.

In our study we opted for the shinbone in reason of this to present a high incidence in sport lesions, mainly for traumas that cause fractures in her medium third and distal. The shinbone presents a hipovascularization and consequently it presents a retard in the consolidation process, bringing as consequences to the patient financial and social costs; associates to long immobilization period, impeding his/her precocious return the professional activities.

Fukada and Yasuda (1957) they demonstrated through study accomplished with human bones that the electric polarization through the action of mechanical load is capable to convert mechanical energy in electric power, being called effect direct piezoelectric then. The inverse is obtained then when an electric field is applied to a material piezoelectric, that is deformed mechanically.

This way we used the ultrasonic stimulation for we believe that if those loads are also produced in the bone through the effect piezoelectric, because the pressed ultrasound reaches the bone fabric as a succession of mechanical pulses, each one of them resulting in an electric sign as answer of the bone and consequently aiding in the process of the bone repair (DOUAT, 2004).

As a consequence of the vibrations of the waves longitudinal mechanical characteristics of the ultrasound, a pressure gradient is developed in the individual cells. As a result of this pressure variation, elements of the cell are forced the if they move, happening, a micromassagem movement, that increases the cellular metabolism, the sanguine flow and the supply of oxygen, producing alteration of the permeability of the cellular membrane and facilitating the flow of nutrients (DYSON & SUCKLING, 1978).

The ultrasound has been used for more than 50 years and some studies have been proposed mainly after the approval of the American organ FDA (Food and Drug Administration) in 1994, in the intention of reaching the bone for therapeutic processes, associated then to the need of acceleration in the bone repair (LIRANI, 2004).

Now they are found several studies that look for the improvement of the process of consolidation bone front to the rehabilitation process, however, they are few the studies that correlate more than a resource fisioterapêutico for this purpose, mainly in association the some type of complementally resource, as for instance, the immobilization.

Duarte e Xavier (1983) it proved in his/her study the beneficial effects of the pressed ultrasound of low intensity in the acceleration of the bone consolidation, for this fact we also believed that the use of UST in this study could present won front to the process of bone consolidation, mainly when associate the a resource thoroughly used in practice it practices medicine that it is the spica cast immobilization, which however, it didn't happen in our work. They affirm that consolidation processes begin soon after the 10th day, we opted in our study for a period of treatment of fourteen days, as form of approximating of the results found by these authors.

It is believed that the use of UST to 10% can interfere in a more effective way close to the process of formation of the bone callus in experimental fractures, because it presents a larger effect osteogenics close to the rehabilitation process and consequently they would present better answer front to the obtained results. However, we observed in this study that the group that received stimulation of UST with intensity of 0,5 w/cm2, just presented a case of bone consolidation, revealing that the intensity parameters and stimulation of UST used in our study, it didn't present results significant front to the process of initial formation of bone callus.

The application of UST in our work took into account established scientific patterns of stimulation and it still used of a headstock reducer as form of addressing the ultrasonic stimulation better. Based on the results obtained in our study, we believed that this reducer might have presented some interference front the refraction of the waves, interfering in the consolidation process.

After every treatment period the choice of the sacrifice was based fifteen days after the accomplishment of the experimental fracture, because studies accomplished by Castro et al (2005) they evidenced the bone consolidation after 14 days of the fracture.

Luger *et al* (1998) they also suggested through their investigations, that the sacrifice of the animals should happen among to 2nd and 4th weeks, because they affirm that in this phase, the bone callus is in ideal phase for analysis.

Lirani (2004) it observed larger osteoclasts prevalence with consequent bone reabsorption in the group treaty with UST of low intensity, while the group treaty with the laser demonstrated larger intensity of cells osteoblastics and osteoides, indicating the prevalence of the phase of bone formation.

In the present study, the group that didn't receive any stimulation type (it controls), it didn't demonstrate any case of formation of bone callus, not corroborating with study of Castro *et al* (2005), in which were observed by evaluation radiographic, the formation of bone callus at the end of the second week powder-fracture.

In compensation, it proved that the fracture type in all of the analyzed groups was always in the same focus, 1/3 medium of the shinbone, same classification and type (transverse and closed). This fracture type for manual pressure provoking closed fracture, it has been effective and used by some authors; Giordano *et al*. (2001) and Santos *et al*. (1993).

Tends in view the qualitative results found in the study radiographic, we suggested the immobilization need during the whole treatment period for better alignment of the fracture and bone consolidation, because the group control presented important deviations close to the bone fragments.

Marino (2003) using of the therapy with laser of low intensity ended that possible reactions as exudates reabsorption with larger agility, increase of the vascularization, and acceleration in the osteosynteses propitiated an effective effect in the bone repair in mouse shinbone.

In our study the group treated with laserterapia (AlGaInP) it presented larger incidence of initial formation of bone callus, corroborating with other investigations in that the therapy with laser of low intensity was demonstrated effective in the treatment of fractures; Freitas *et al.* (2000) e Garavello *et al*. (2003).

Trelles and Mayayo (1987) they used the laser He-Ne in fractures of shinbone of mice where later it was made histological analysis presenting an important increase in the vascularização and faster formation of bone fabric during twelve sessions, tends beginning in the postoperative immediate.

Freitas (2001) the effects of the laser were investigated HeNe, with low exit potency, through different doses therapeutics (3,15; 31,5 and 94,5 J/cm2), being accomplished the histological analyses that you/they demonstrated the formation of thicker bone trabeculs and acceleration of the angiogenesis, indicating that an increase in the synthesis of fibers collagens and activity osteoblastics happened for the irradiation of the laser of low potency, accelerating the fracture repair, fact this also observed in this study.

Evaluations radiologic were only accomplished in an incidence, for that, we believed that you improve results could be observed in other incidences as AP and profile that are more trustworthy in the analysis of formation of bone callus in the focus of the fracture, being evidenced like this such need. We still suggested for future studies that the use of other modalities and parameters of UST are accomplished, so that you improve results can be compared and reached. It is still, the adoption of other immobilization techniques as internal and external fixations of treatment, as form of prophylaxis front to the alignment of the fracture focus and improvement in the process of bone consolidation.

CONCLUSION

Our study suggests himself that the therapy with laser of low intensity was capable to accelerate with larger effectiveness the initial formation of bone callus in relation to the experimental groups. However, it was possible still to evidence that the use of UST also presents his/her contribution front to this process, however with smaller incidence, what suggests the need of accomplishment of larger studies front close to the verification of the contribution of this resource the process of bone repairing.

REFERENCES

BOOTH, F.W.; KELSO, J.R. Protection of rat muscle atrophy by cast fixation. **J of Applied physiology.** v.34, n.3, p.404-406, 1973.

CASTRO, P.C.F.*et al* Estudo do processo de consolidação óssea em ratos tratados com acetaminofen: avaliações radiográfica e histológica. **Rev Bras Ortop**. Rio de Janeiro. v.40, n.10, p.614-620, 2005.

CHANG, W.H. *et al*. Study of thermal effects of ultrasound stimulation on fracture healing. **Bioelectromagnetics**. v.23, n.4, p.256-264, 2000.

COOMBLE, A. R. *et al*. The effects of low level laser irradiation on osteoblastic cells. **Journal of Clinical Orthodontics & Craniofacial Research.** Canada, v.4, p. 3-14, 2001.

DOUAT, E.S.V. **Estudo comparativo do efeito do UST de 1 MHz com freqüência de repetição de pulso a 100 Hz e 16 Hz no reparo de osteotomia por escareação em tíbia de rato**, 2004, 74 f. Dissertação de Mestrado. Escola de Engenharia de São Carlos/Faculdade de Medicina de Ribeirão Preto/Instituto de Química de São Carlos, Universidade de São Paulo, São Carlos, 2004.

DYSON, M.; SUCKLING, J. Stimulation of repair by ultrasound: a survey the mechanism involved. **Physiotherapy.** v.64, n.4, p.105-108, 1978,

DUARTE, L. R.; XAVIER, C.A.M. Estimulação Ultrasônica do Calo Ósseo. Aplicação Cínica. **Revista Brasileira de Ortopedia.** Rio de Janeiro, v.101, p.153-159, 1983.

FREITAS, I. G. F. **Ação do laser de HeNe na osteogênese**. Tese de Doutorado. 83 f. Faculdade de Engenharia Elétrica e Computação da Universidade Estadual de Campinas. São Paulo, 2001.

FREITAS, I. G. F.; BARANAUSKAS, V.; CRUZ-HOFLING, M.A. Laser effects on osteogenesis. **Applied Surface Science.** v.154, p.548-554, 2000.

FUKADA, E.; YASUDA, I. On the Piezoeletric Effect Bone. **Journal of the Physical Society on Japan**, v.12, n.10, p. 1158-1162, 1957.

GARAVELLO, F. I. *et al*. Low-power laser irradiation improves histomorphometrical parameters and bone matrix organization during tibia wound healing in rats. **Journal of Photochemistry and Photobiology**, v.70, p.81-89, 2003.

GIORDANO, V. *et al*. Influência do laser de baixa energia no processo de consolidação de fratura de tíbia: estudo experimental em ratos. **Revista Brasileira de Ortopedia**. Rio de Janeiro, v.36, n.5, 174-178, 2001.

HECKMAN, J.D.; SARASOHN-KAHN, J. The economics of treating tibia fractures. The cost of delayued unions**. Bulletin of the Hospital for Joint Diseases.** v.56, p.63-72, 1997.

LEWIN, P.A.; ZISKIN, M.C. An Overview of Ultrasonic Exposimetry and Clinical Relevance. *In*: Ziskin MC, Lewin PA. **Ultrasonic exposimetry**. Boca Raton: CRC Press, Cap. 1, p.1-8, 1993.

LIRANI, A. P. R. **Estudo Comparativo dos Efeitos do Ultra-Som e do Laser de Baixa Intensidade no Reparo Ósseo de Tíbia de Rato**, 2004, 94 f. Dissertação de Mestrado Escola de Engenharia de São Carlos/ Faculdade de Medicina de Ribeirão Preto/ Instituto de Química de São Carlos, Universidade de São Paulo, 2004.

LUGER, E. J. *et al*. Effect of low-power laser irradiation on the mechanical properties of bone fracture healing in rats. **Lasers in Surgery and Medicine**.v.22, n.2, p.97-102, 1998.

MARINO, J. A. M. **Efeito do laser terapêutico de baixa potência sobre o processo de reparação óssea em tíbia de rato.** Dissertação Mestrado. Universidade Federal de São Carlos, São Carlos, 2003.

MATHEUS, J.P.C. *et al.* Effects of therapeutic ultrasound on the mechanical properties of skeletal muscles after contusion**. Revista Brasileira de Fisioterapia,** São Carlos, v.12, n.3, p.241-247, 2008.

SANTOS, D. L. P. *et al*. Estudo das alterações da placa epifisária distal do fêmur do rato após fratura ao nível da diáfise. **Revista Brasileira de Ortopedia**. Rio de Janeiro, v. 28, n.9, p.662-666, 1993.

TRELLES, M.A.; MAYAYO, E. Bone fracture consolidates faster with low-power laser. **Lasers ind Surgery and Medicine**. v. 7, p.36-45, 1987.

USE OF THE THERAPEUTIC ULTRASOUND AND LASER THERAPY IN THE INITIAL FORMATION OF BONE CALLUS

ABSTRACT

The present study the application of irradiation with laser in the initial formation of osseous callus in association to spica cast had as objective to verify the effect of the application of the UST (therapeutical ultrasound) of comparative. The study it used of eighteen rats, with average corporal weight of 380g. All the procedures had been carried through in compliance with the norms and ethical principles in research with animals and approved by CEP - UNIARAXÁ. The animals had been divided in three experimental groups (A, B and C) composites for six animals each. The animals had been submitted to the experimental production of the fracturing in the right tibia, produced to the level of the 1/3 tibial distal, through manual pressure, being that after the production of the fractures all the groups had been immobilized with spica cast device. In the group associate to the stimulation with UST was carried through it IG (1MHz, pulsed: 50%, intensity: 0,5 W/cm2); in group B the animals had been submitted IG and applied the laser pontual in 4 J/cm2, and group C it served only of control of the study, being only submitted to the protocol of spica cast immobilization. For the analysis of initial formation of osseous callus, after the period of treatment, the animals f all the groups had been day sacrificed and carried through radiographic examinations in the posterior-previous incidence in 15º day. In the radiographic analysis of the group dealt with laser, the beginning of formation of osseous callus was greater that the too much groups. We suggest through the joined results that the UST sped up the osseous repair, however, the laser was capable to speed up with bigger potentiality the initial formation of osseous callus in relation to the other analyzed groups.

Key-words: fractures, ultrasound, laser.

UTILISATION DE L'ULTRASON THÉRAPEUTIQUE ET LASERTERAPIA DANS LA FORMATION INITIALE DE CALUS OSSEUX

RÉSUMÉ

Présente étude il a eu comme objectif vérifier les effets de l'application de UST (Ultrason thérapeutique) comparée à l'application d'irradiation avec laser dans la formation initiale de calus osseux dans association à l'immobilisation gessada (IG). Ont été utilisés dix-huit rats d'avec poids corporel moyen de 380g. Tous les procédures ont été réalisés conformément aux normes et aux principes moraux dans recherche avec des animaux et approuvée par CEP-UNIARAXÁ (Comité d'Éthique et Recherche - UNIARAXÁ). Les animaux ont été divisés dans trois groupes expérimentaux (A, B et C) composés de six animaux

chaque. Les animaux ont été soumis à la production expérimentale de la fracture dans le tibia droit, produites au niveau du 1/3 distal tibial, à travers pression manuelle, en étant ultérieurement immobilisés avec appareil gessado. Dans le groupe L'a été réalisée IG associé à la stimulation avec UST (1MHz, battue 50%, intensité de 0.5 W/cm2) ; Groupe B les animaux ont été soumis IG et appliqué le laser rapide à 4 J/cm2 et le groupe C il a servi seulement de contrôle de l'étude, en étant soumise seulement au protocole de IG. Pour l'analyse de formation initiale de calus osseux, après la période de traitement, les animaux de tous les groupes ont été sacrifiés et réalisés des examens radiographiques dans l'incidence póstero-anterior dans la 15º jour. Dans l'analyse radiographique du groupe traité avec laser le début de formation de calus osseux a été plus grand que les autres groupes. Nous suggérons à travers les résultats trouvés que UST a accéléré la réparation osseuse, néanmoins, le laser a été capable d'accélérer avec plus grande potentialité la formation initiale de calus osseux concernant les autres groupes analysés.

Mots clés: fractures, ultrasons, laser.

USO DE LA ULTRA-SOUND TERAPIA CON LÁSER Y LA FORMACIÓN INICIAL DE CALLO ÓSEO

RESUMEN

Este estudio tuvo como objetivo verificar los efectos de la aplicación de UST (terapia de ultrasonidos) en comparación con la aplicación de la irradiación láser en la formación inicial de callo óseo en asociación con la detención enyesado (FC). Se utilizaron dieciocho de ratas con peso promedio de 380g. Todos los procedimientos se realizaron de conformidad con las normas y los principios éticos en la investigación sobre los animales y aprobado por el CEP-UNIARAXÁ (Comité de Ética e Investigación - UNIARAXÁ). Los animales fueron divididos en tres grupos experimentales (A, B y C) que consta de seis animales cada uno. Los animales fueron sometidos a la producción experimental de la fractura de tibia derecha, producida en el 1/3 distal tibia a través de la presión manual y, posteriormente, detenidos junto con los aparatos de enyesado. En el Grupo A se hizo al FC asociados con la estimulación UST (1MHz, pulso 50%, la intensidad de 0,5 W/cm2), el Grupo B los animales fueron sometidos a IG y aplicó el láser in situ a 4 J/cm2 y el grupo C sólo sirve para controlar el estudio, sólo están sometidos al protocolo de FC. Para el análisis de la formación inicial de callo óseo, después de que el período de tratamiento, los animales de todos los grupos fueron sacrificados y los rayos X realizados sobre la incidencia posterior-anterior en 15 días. En el análisis radiográfico del grupo tratado con láser a partir de la formación de callo óseo fue superior a los otros grupos. Sugerimos la utilización de los resultados determinó que la UST acelerado la curación del hueso, sin embargo, el láser es capaz de acelerar con mayor potencial de la formación inicial de callo óseo en relación con otros grupos.

Palabras clave: fracturas, ultrasonido, laser.

UTILIZAÇÃO DO ULTRA-SOM TERAPÊUTICO E LASERTERAPIA NA FORMAÇÃO INICIAL DE CALO ÓSSEO

RESUMO

O presente estudo teve como objetivo verificar os efeitos da aplicação do UST (Ultra-som terapêutico) comparado à aplicação de irradiação com laser na formação inicial de calo ósseo em associação à imobilização gessada (IG). Foram utilizadas dezoito ratas de com peso corporal médio de 380g. Todos os procedimentos foram realizados em conformidade com as normas e princípios éticos em pesquisa com animais e aprovada pelo CEP-UNIARAXÁ (Comitê de Ética e Pesquisa UNIARAXÁ). Os animais foram divididos em três grupos experimentais (A, B e C) compostos por seis animais cada. Os animais foram submetidos à produção experimental da fratura na tíbia direita, produzidas ao nível do 1/3 distal tibial, através de pressão manual, sendo posteriormente imobilizados com aparelho gessado. No grupo A foi realizado a IG associada à estimulação com UST (1MHz, pulsado 50%, intensidade de 0,5 W/cm^2); Grupo B os animais foram submetidos a IG e aplicado o laser pontual a 4 J/cm^2 e o grupo C serviu apenas de controle do estudo, sendo submetido somente ao protocolo de IG. Para a análise de formação inicial de calo ósseo, após o período de tratamento, os animais de todos os grupos foram sacrificados e realizados exames radiográficos na incidência póstero-anterior no 15º dia. Na análise radiográfica do grupo tratado com laser o início de formação de calo ósseo foi maior que os demais grupos. Sugerimos através dos resultados encontrados que o UST acelerou o reparo ósseo, porém, o laser foi capaz de acelerar com maior potencialidade a formação inicial de calo ósseo em relação aos outros grupos analisados.

Palavras-chave: fraturas, ultra-som, laser.