120 - CASE STUDY REHABILITATION TENORRHAPHY ACHILLES TAPING BY NEUROMUSCULAR

YANETH RIVERA GÓMEZ
Universidad de Cundinamarca. Programa Ciencias del Deporte
Soacha, Cundinamarca, Colombia
yanethrivera2005@yahoo.com

INTRODUCTION

The Achilles tendon or tendon calcaneus, is one of the most powerful found in the human body. It is characterized by fibrous connective tissue that is inserted by a muscle to a bone. The tendon has a milky white color, strong consistency and non-contractile capacity. It consists of the gastrocnemius and soleus muscles. Twins have two heads, one medial and one lateral, medial head originates from the medial femoral condyle popliteal face, head and lateral lateral femoral condyle, the origin of the soleus muscle is in the head of the fibula and 1 / 3 diafisiario shaft proximal tibia and the popliteal line. The three are inserted into the base posterior calcaneal tuberosity and higher. The action of these muscles is plantarflexion, having a range of motion from 0 to 45 °. The innervation is given by the posterior tibial nerve to the sural triceps twins (s1, s2) and for soleus nerve at the same (L5-S2). Worthingham's D (2002)

There is a structure located between the bone and the tendon called retrocalcaneal bursa, serves as lubrication-damping. When performing plantarflexion generates propulsion during walking, enduring strength up to 10 times body weight. The tendon is surrounded by a tissue called paratenon which presents no synovial sheath structure. The paratenon is peritendinous connective tissue completely surrounding the Achilles tendon. Tendon vascularity varies according to its length, where the circulation is increased in the distal part of its insertion into the calcaneus, where the vessels begin to diminish in number and in distribution as tendon away from its insertion (4 cm. away).

According to epidemiology is the third most common injury, followed by rotator cuff injury and quadriceps, more frequently in men than in women and it is estimated that this injury is associated with occupational activities or job type. Nationally it is estimated that 75% of her Achilles tendon lesions occur in athletes, particularly in athletes, people between 30 and 40 years, and is more common in sedentary work activities, because the decrease active movement speeds the process of atrophy and weakness osteoartromiokinemáticas structures.

The etiology is related to three factors: the mechanical factor, which generates a violent dorsiflexion in the foot and a direct hit while the muscle is contracted. After a complete break, the person experiences sudden pain and a snapping sensation. The vascular factor, presenting a limitation to be a hypovascular area, the most common place for the break is at a distance of 2-6 cm from the calcaneus. Is the area where usually appears tendinitis due perhaps because of poor blood flow. The third and final factor is related to the integrity of tissues and associated with a pathological process prior to the tendon. Degenerative changes weaken one area that if placed under excessive stress can break. Lagergren, C. (1958)

Risk factors that cause the Achilles tendon injury occurs in sports activities conducted weekend previous areas with tendinosis or intratendinous degeneration, history of gout, because the formation of uric acid crystals cause rupture or tenosynovitis, hiperpronado presence of a foot, hyperlipidemia characterized by the deposition of lipids and sterols in the blood and soft tissues, resulting in weakness and favoring tendon rupture. Diabetes mellitus due to the presence of metabolic causes painless tendinitis that increase the risk of rupture and release of the tendon.

The generating mechanisms of injury are due to direct trauma to the tendon, common during certain sporting activities such as football, stretching sudden, forced dorsiflexiones when the joint standing neck is relaxed and not ready for the stress and displacement body forward with the heel fixed.

For diagnosis, during titration may notice a palpable defect of the Achilles tendon at the site that the rupture was presented with ecchymosis which may be some distance from the site of rupture due to the effects of gravity. To evaluate this injury is the positive sign of Thompson, is to generate pressure on gastronemios with the knee flexed, the immediate reaction should be a plantar flexion. When Achilles tendon rupture, plantar flexion that is absent.

The injury can be classified according to the chronology bearing in mind the time of evolution, can be acute, subacute or chronic. In those lesions in which it has been more than two weeks, the tendon retracts and the space between the broken ends is occupied by scar tissue, slowing the recovery process. According to the severity of the injury, there may be complete or partial ruptures. According to the direct and indirect generating mechanism.

The Achilles tendon injury occurs either by tearing of some fibers of the MTJ to the distal part of the tendon that attaches to the base of the calcaneus, or a total rupture of the tendon. This injury is the third of the tendon ruptures after injury to the rotator cuff muscles and the quadriceps. Kenzo K, (1998)

Surgery to repair the Achilles tendon (tenorrhaphy) is surgery in which the tendon is sutured. It is an application of gypsum podalic thigh ankle equinus position. In rare cases, but the recovery is immobilized is much more delayed in the healing process.

The clinical case corresponds to a 65-year-old, who presented Achilles tendon rupture on August 23, 2012 after a fall that was that to take the step, left foot got all your weight to height of between 80 cm and one meter above the ground. Upon arriving at the clinic referred pain in the back of the ankle, tenderness in the left leg associated with mild swelling and bruising. A valuation was carried Thompson sign which was positive. The patient presents as hypertension medical history for 15 years, diabetes mellitus type II five years ago, three years ago, rheumatoid arthritis and gout 15 years ago. After the diagnosis is referred to schedule surgery to repair the Achilles tendon (tenorrhaphy). After surgery the foot is immobilized double braced front and back of the left leg and was discharged. The doctor suggests that the foot was completely still and with the tip down in plantarflexion.

The rehabilitation process was divided into three phases: The first phase consisted of the scar to protect, manage pain and inflammation, prevent muscle atrophy and weight control support generated splints. During this stage the splint was recommended to use before and after the walk during the day and night, to be withdrawn by the third week.

After 15 days of surgery Physiotherapy started making revision of the wound which had already been removed points. It showed some infection and scar coloration, two points had not healed completely. The foot was in full plantarflexion and inversion mild. At that time the application started taping for handling NEUROMUSCULAR healing, pain and swelling in the area of the foot, medial malleolus, external, and dorsum of the foot with the back foot in the path of the Achilles tendon . The patient

complained of discomfort from the weight of the splint. He also expressed discomfort, permanent discomfort, tingling and discomfort with the first application of TAPING NEUROMUSCULAR.

For wound healing applications were made around the affected area, circulation stimulating tissue healing accelerated thanks to its physiological effect on the mechanoreceptors. TAPING applications were made to decrease inflammation NEUROMUSCULAR foot, foot and neck of rear specifically in the area of the scar. Additionally silicone bands were used to improve the healing process and preventing keloid formation because the patient has diabetes mellitus type II and the healing process is well hypertrophic be late. It took into account the use of silicone bands because they achieve the volume decrease scarring and increase the elasticity of the skin by 60% generated by the increased permeability of the fabric, the development of electrostatic forces. Hashimoto and Tomoki O, (1996) and the step of silicone microparticles skin. Kenzo K, (1997).

Although pathophysiologically tendon healing, unlike what occurs in the healing of soft tissue bulk requires a dense fibrous union of the separated ends and extensibility and flexibility at the junction site, so abundant collagen is needed to achieve adequate tensile strength. However, the synthesis of collagen can be excessive, resulting in fibrosis adhesions that form the surrounding tissues that interfere with the sliding movement essential for proper. With the passage of time, the surrounding tissue healing acquires an elongated structure due to the breaking of cross-links between fibrin units, allowing the necessary sliding movement for driving. During the second week about the tendon attaches to the surrounding tissue to form a single mass. During the third week the tendon is separated into different grades of surrounding tissues. However, the tensile strength is insufficient to allow the tendon effort to take at least 4 or 5 weeks. Prentice, W (2000). Tendon healing is done under conditions of low blood supply and need to produce large amounts of collagen. So after tendon graft repairs or prolonged immobilization is essential for at least 6 to 8 weeks. However, the immobilization produces significant complications such as muscle atrophy or joint stiffness, resulting in a slow recovery, even a severe functional limitation for the patient. Enwemeka, C (1992). In consequence of the above, the use of neuromuscular TAPING with silicone bands accelerated the healing process in less time than theoretically estimated for the healing of connective tissue.

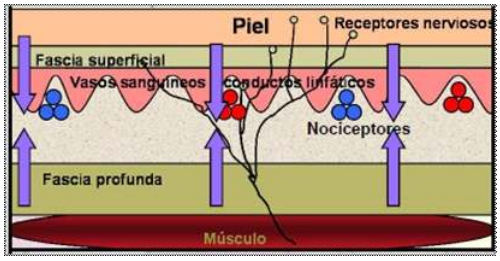

Taping neuromuscular circulatory effect. Josya S (2007)

The process at the tendon traumatic rupture caused causes the manifestation is the presence of inflammation, which in turn produces an increased pressure on adjacent tissues that are causing a decrease of the space between the skin and muscle, causing the evacuation lymphatic and blood circulation are much slower and decrease, so there is a pressure increase of nociceptors and therefore increased pain. The mechanism of action of neuromuscular TAPING circulatory level, causes a slight rise is present on the skin, skin folds forming surface noticeable. These skinfold normally not formed in any position in which the area to be available, the action of wide TAPING subcutaneous space between perilymphatic capillaries, the capillaries and different receivers afferent and efferent, and immediately reduces pressure mechanoreceptors thereby restores blood circulation and lymphatic drainage, allowing the reduction of the inflammatory process and makes the pressure is decreased on nociceptors reducing pain.

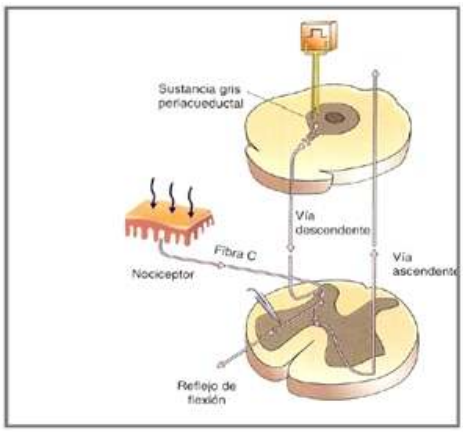

Analgesic effect of neuromuscular taping. Josya S (2007)

NEUROMUSCULAR taping was applied not only to treat the injury but for the maintenance of the other segments (strengthening of respiratory muscles, muscles of upper limbs and trunk, for subsequent use crutches with conservation respiratory capacity).

RICE method was performed. Rest, ice, compression, elevation and stabilization of the affected segment during the first month. Initiated a submaximal isometric exercise program at two weeks, hip abduction and adduction, flexion, hip extension and knee and internal and external rotation of the hip. Concentric and eccentric isotonic exercises for strengthening the respiratory muscles lose strength during the quiet period and immobilization. Isotonic exercises strengthen the muscles of the shoulder, elbow, forearm, wrist and fingers along with the trunk in preparation for the use of crutches.

Phase I of immediate protection according to protocols used in the conventional manner has a length of up to 4 weeks,

with the use of NEUROMUSCULAR TAPING was reduced to three weeks due to the effect generated by the application of the technique for tissue healing together with inhibition technique in twins. The patient stated that the use of TAPING began to notice that the muscles were stronger, as witnessed by the increase in muscle volume. During the first month the foot maintained 45 ° of plantarflexion, reducing the tension of the Achilles tendon to promote healing of connective tissue.

During phase II, followed by protecting the repaired tissue and reduced the stress generated on the sutured tissue. Worked on reducing pain and inflammation and promoting empowerment. The muscles in which we used the activation technique were the anterior tibial and peroneal, inhibition was performed on gastrocnemius and soleus mindful origin and insertion. NEUROMUSCULAR TAPING action in anterior tibial and peroneal favored strengthening and muscle activation to that during the rehabilitation process was not lost strength and was preserved which was present. Application was made in the rectus femoris of the quadriceps with ligament technique medial and lateral side on the knee joint

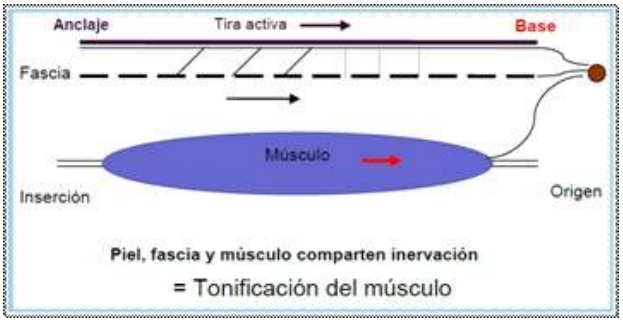

Activation and inhibition effect of neuromuscular taping. Josya S (2007)

At the end of the sixth week joint test was performed for dorsiflexion, determining that the foot came into neutral, which means that the activation technique through the anterior tibial TAPING facilitated neuromuscular dorsiflexion movement, improving strength and I said trophism muscle. The pain was reduced by 80%. Continued progression to full range of motion in dorsiflexion, along with exercises to improve proprioception, strength, power and endurance through media arches squats with body weight initially and then with 2 kg. By the eighth week, the patient began to block march forward, backward, lateralizaciones, up and down stairs accompanied by crutches. Phase II according to the protocols used conventionally has a duration of 4 to 8 weeks, with the use of NEUROMUSCULAR TAPING was reduced to 6 weeks.

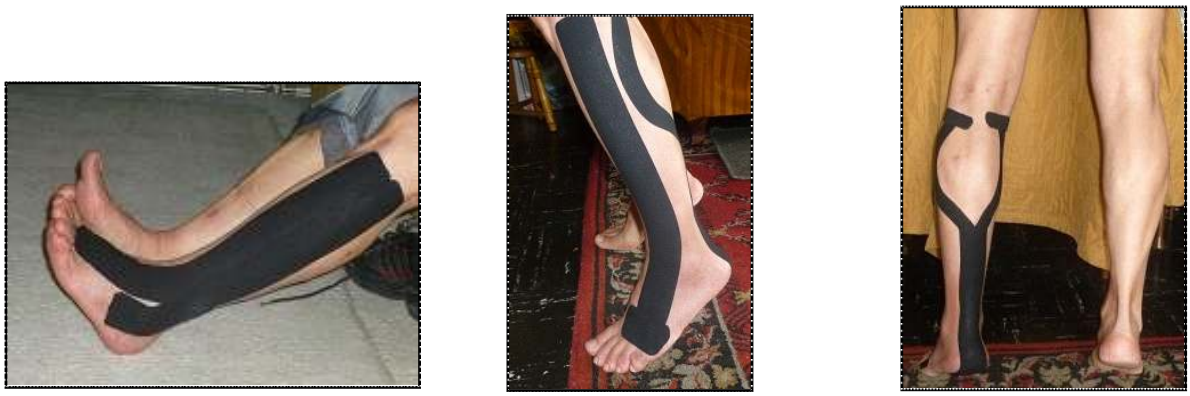

Application TAPING in tibialis anterior, peroneal and twins

During the interview the patient mentioned "Something that really impressed me is to see that there are things that the affected foot does better than the good foot and that the only thing that shows is that neither of them was doing well before the injury. Mechanization Because I have, is not adequate. The affected foot had to unlearn to relearn but learned right from walking, while the healthy foot does, but improperly machined, which means that bad accustomed, kept the previous routine was something I always went wrong. "Interview the patient (2012).

In the third phase or return to activity, continued the building program. The patient was rejoined to the activities of daily living and working in a span of two months. Performing a march in which unlearned movements to incorporate properly again. The return phase activity lasts for 5-7 months usually, but thanks to the action of NEUROMUSCULAR TAPING was reduced to two months.

The patient reported that "at the time I did support the injured foot was the first time that the two months after surgery I felt I could walk and I felt good. Best I've felt yet the most impressive thing was to go downstairs without my help. (With crutches could do alone) felt a degree of freedom and independence. During the time it is immobilized feels like a prisoner, but when I first felt support freedom. And feeling like you have leg again. I found it very important after support when I started the march and start to break down the movements of walking and start rebuilding them without altering the entire foot, which required an initial process block up from the hip and then stopping to look each phase. And that's where we understand all those anatomical changes that you have and if it was not for the injury I had ever realized. When going to walk with crutches to do without them, it was like he knew walk to remember but that action makes one in some machining. One lives at every moment but it is conscious. And wealth is not aware that it is walking and deprivation of not being able to move one. Walking with crutches is something very limiting. Remembering is important and creates an incentive to try to get it right, and I realized that I have never walked well. Because by trying to do it the right way, ie fulfilling each phase as it should be, I got tired too. I feel now after all the rehabilitation process two months, gain strength. "Interview the patient (2012).

THEORETICAL CONCLUSIONS

The physiological effect of NEUROMUSCULAR TAPING postoperatively, was reduced rehabilitation time between 5 and 7 months on average, two months. The return to work activities was much faster than if the treatment had been performed conventionally, considering the patient's history along with age, would retard the recovery process tenorrhaphy.

The mechanism of action of neuromuscular TAPING circulatory level, extends the subcutaneous space between perilymphatic capillaries, the capillaries and different receivers afferent and efferent, and immediately reduces pressure mechanoreceptors thereby restores blood circulation and lymphatic drainage, allowing reduction of the inflammatory process causing the pressure is decreased on nociceptors reducing pain.

From the viewpoint neurophysiological considered that voluntary movement depends on the perception of superficial and deep feeling, and strength and coordination. All movements of the body are performed in response to sensory stimuli which act on the central nervous system from the outside through the exteroceptors. We must understand that the direction, scope, speed, strength and coordination of a particular movement directly under the feed-back given by mecanorreceptivo afferent system, which constantly sends input to modify or enhance the movement in question, and in the afferent system mecanorreceptivo, afferent information given by the skin and fascia is one of the most abundant and rich in this regulation of normal movement.

CONCLUSIONS FROM HUMAN PATIENT

There are two key components in the process: The conscious and unconscious. The conscious related to how interesting it is to understand that actions that are machined in humans, such as breathing, eating and walking are very complex things if they break step means that each party depends on the other to work in harmony during movement. The unconscious is in NEUROMUSCULAR TAPING, who begins to exert a number of functions, triggers and developments very quickly in recovery. It is a way of feeling a recovery and a rapid change without them feels strange.

The NEUROMUSCULAR TAPING generated greater patient safety at the time of active exercises. I also believe that the patient explain the why, what and how does the taping or every thing you do in recovery is essential in the rehabilitation process.

It is important to understand that the most artificial and human as you leave one in the field of spontaneity and not given a whole process of training and development. It is important to unlearn shares re-learn walking, making conscious movement. We must recover the sense of harmonic motion and order the same.

I also feel that one has many flaws gear, structural failures, which not educated one at that, rather one can not walk, then they are wrong gait of life that if you do not fix them, not only damages but uses more energy as it is. And if this situation has not been filed and I do not see him die.

Only when an injury is when we value the importance of human movement. Structural defects from gait and posture, fundamental stock for each share of daily life. Something important is to realize that apparently thinks the arm movement has nothing to do with the foot, but if you do not move your arms well not be able to move your feet. If not breathing, you do not have energy to do so. Then I realized the importance of everything and as a whole is directly related to walking.

REFERENCES

1. Advanced Technique Kinesio KenzoKase, Tokyo, Kinesiotaping Association, 1998

2. Application Techniques KenzoKase and Jim Wallis, Kinesiotaping

3. Clinical Therapeutic Applications of the Kinesio Taping Method2 th Edition, Kenso Kase, Jim Wallis, Tsuyoshi Kase, 2003.

4. Interview the patient on November 2, 2012

5. Enwemeka, CS: Functional loading augments the initial tensile strength and energy decrease absorption capacity of regenerating rabbit Achilles. tendons. Am J Phys Med Rehabil, 71: 31-38, 1992

6. Okane Tomoki Hashimoto, Tokyo, Ken Ikai Information, 1996

7. Har-Shai Y, Lindenbaum E, Tendler M, et al. Negative charged static electricity stimulation as a possible mechanism for Enhancing the involution of hypertrophic and keloid scars. IMAJ 1999, 1: 203-10.

8. Illustrated Kinesio taping, KenzoKase, Tokyo, Ken IkaiInformation, 1997

9. Lagergren C, Lindholm A: Vascular Distribution: the achilles tendon, Acta Chir Scand, 1958.

10. Niessen FB, Spauwen M, Schalkwijk J, Kon M. On the nature of hypertrophic scars and keloids: A review. PlastReconstrSurg 1999, 104: 1435-1458.

11. William Prentice. Rehabilitation Techniques in Sports Medicine. Editorial. Paidotribo. 2nd edition (2000).

12. Muscular TapingNeuro, Josya Sijmonsma, 1st EdicionEspañola, AneidPress, Cascais, 2007

13. Wills A C MD, Washburn S M, Caiozzo V. Achilles Tendon Rupture: A Review of the Literature Comparing Surgical Repair versus Non Surgical Treatment. Clin Orthop Rel Res 1986.

14. Worthingham's Daniels, J. Hislop Helen, Jacqueline Montgomery. Muscle Functional Tests. Manual scanning techniques. 6 Edition. Editorial Marban. 2002.

CASE STUDY REHABILITATION TENORRHAPHY ACHILLES TAPING BY NEUROMUSCULAR

ABSTRACT

The Achilles tendon is the completion of three muscles, gastrocnemius, soleus and plantaris who in turn form the sural triceps. This muscle group is attached to the tendon which is inserted into the posterior surface of the calcaneus bone at the heel, are responsible for the plantar flexion of the foot. The Achilles tendon rupture is increased by the high rate of physical inactivity and increased people doing sport eventually, but with a lower index are athletes. People with this type of injury manifest pain in the back of your neck stand them impossible to perform plantar flexion. Factors have been identified that will enhance it more often this tendon rupture such as the failure to conduct a proper warm up before any sport and chronic degenerative diseases of the body. Although in some cases surgery is performed, the treatment is more tenorrhaphy choice, that is to make an end of suture which has been ruptured tendon. The mechanism of action of NEUROMUSCULAR TAPING circulatory level causes an increase in the subcutaneous space between perilymphatic capillaries, the capillaries and different receivers afferent and efferent, and immediately reducing the pressure of mechanoreceptors, pain level generates a reduced nociceptors pressure reducing pain levels almost immediately.

KEYWORDS: Tendon, surgery, rehabilitation, neuromuscular taping, mechanoreceptors

ÉTUDE DE CAS DE RÉHABILITATION TENORRHAPHY ACHILLE TAPING PAR NEUROMUSCULAIRE

RÉSUMÉ

Le tendon d'Achille est l'achèvement de trois muscles gastrocnémiens, soléaire et plantaire, qui à leur tour forment les triceps sural. Ce groupe musculaire est fixé par rapport au tendon, qui est inséré dans la surface postérieure de l'os calcanéum au niveau du talon, sont responsables de la flexion plantaire du pied. La rupture du tendon d'Achille est augmentée par le taux élevé d'inactivité physique et le sport a augmenté gens qui font par la suite, mais avec un faible indice sont des athlètes. Les personnes atteintes de ce type de douleur manifeste une blessure à l'arrière de votre cou se impossibles à effectuer une flexion plantaire. Facteurs ont été identifiés qui va le plus souvent de renforcer cette rupture du tendon tels que la non-réalisation d'un bon échauffement avant tout le sport et les maladies chroniques dégénératives du corps. Bien que, dans certains cas, la chirurgie est pratiquée, le traitement est plus tenorrhaphy choix, c'est de faire une fin de suture qui a été rupture du tendon. Le mécanisme d'action du niveau TAPING circulatoire neuromusculaire provoque une augmentation de l'espace sous-cutané entre périlymphatique capillaires, les capillaires et les différents récepteurs afférents et efférents, et immédiatement à réduire la pression des mécanorécepteurs, le niveau de douleur produit une diminution pression nocicepteurs la réduction des niveaux de douleur presque immédiatement.

MOTS-CLÉS: tendineuses, chirurgie, rééducation, taping neuro-musculaire, mécanorécepteurs

ESTUDIO DE CASO REHABILITACIÓN DE TENORRAFIA DEL TENDON DE AQUILES POR MEDIO DE TAPING NEUROMUSCULAR

RESUMEN

El tendón de Aquiles es la terminación de tres músculos, gastronemio, plantar delgado y soleo quienes a su vez conforman el tríceps sural. Este grupo muscular se une en el tendón que se inserta en la superficie posterior del calcáneo, hueso que forma el talón, son los encargados de la flexión plantar del pie. La ruptura del tendón de Aquiles se ha incrementado por el alto índice de sedentarismo y el aumento de personas que realizan práctica deportiva eventualmente; sin embargo, con un menor índice se encuentran los deportistas. Las personas que presentan este tipo de lesión manifiestan dolor en la región posterior del cuello de pie que les imposibilita para realizar la flexión plantar. Se han determinado algunos factores que potencializan que sea más frecuente la ruptura de este tendón como por ejemplo la no realización de un adecuado calentamiento antes de cualquier práctica deportiva y algunas enfermedades crónicas degenerativas del organismo. Aunque en algunos casos no se realiza la intervención quirúrgica, el tratamiento con mayor elección es la tenorrafia, que consiste en hacer una sutura de los extremos del tendón que ha sufrido ruptura. El mecanismo de acción del TAPING NEUROMUSCULAR a nivel circulatorio hace que se aumente el espacio subcutáneo entre los capilares perilinfáticos, los vasos capilares y diferentes receptores aferentes y eferentes; e inmediatamente disminuyendo la presión de mecanoreceptores, a nivel de dolor se genera una disminución de la presión sobre los nociceptores reduciendo los niveles de dolor de manera casi inmediata.

PALABRAS CLAVES: Tendón, cirugía, rehabilitación, taping neuromuscular, mecanoreceptores

REABILITAÇÃO ESTUDO DE CASO TENORRAFIA TAPING AQUILES POR NEUROMUSCULAR

RESUMO

O tendão de Aquiles é a conclusão de três músculos, gastrocnêmio, sóleo e plantar, que por sua vez formam o tríceps sural. Este grupo está ligado ao músculo do tendão, que é inserido para dentro da superfície posterior do osso calcâneo no calcanhar, são responsáveis pela flexão plantar do pé. A ruptura do tendão de Aquiles é aumentada pela alta taxa de inatividade física e aumentou pessoas fazendo esporte, eventualmente, mas com um menor índice são atletas. As pessoas com este tipo de dor lesão manifesta na parte de trás do seu pescoço stand-los impossível realizar flexão plantar. Fatores foram identificados que vai melhorar isso mais vezes esta ruptura do tendão, como a não realização de um bom aquecimento antes de se qualquer esporte e doenças crônico-degenerativas do corpo. Embora, em alguns casos, a cirurgia é realizada, o tratamento é a escolha mais tenorrafia, que é fazer com que uma extremidade do fio de sutura que foi tendão rompido. O mecanismo de acção do nível neuromuscular TAPING circulatório causa um aumento no espaço subcutâneo entre perilinfática capilares, os capilares e os receptores diferentes aferentes e eferentes, e imediatamente a reduzir a pressão de mecanorreceptores, nível de dor gera uma reduzida pressão nociceptores reduzindo os níveis de dor, quase imediatamente.

PALAVRAS-CHAVE: Tendão, cirurgia, reabilitação, gravação neuromuscular, mecanorreceptores