73 - ELECTROLIPOLYSIS IN THE REDUCTION OF ABDOMINAL MEASUREMENTS: A CASE STUDY

ELIANA NUNES DA SILVA
EMILIANA ELIAS CAMBOIM
EDINEIDE NUNES DA SILVA
ANA MARIA BRAGA DE OLIVEIRA
ADILVANIA FERREIRA DA COSTA (ORIENTADORA).
FACULDADE SANTA MARIA - DEPARTAMENTO DE FISIOTERAPIA.
CAJAZEIRAS-PB, BRASIL.
waniafisio@yahoo.com.br

INTRODUCTION

Lipodystrophy, popularly known as localized fat, affects mainly women, for whom besides being unsightly, it causes functional and even emotional problems, affecting self-esteem, the main source of security of women, and sometimes also leading serious health problems, which often appear in association, requiring a complete treatment, with all the signs of bodily disharmony. Besides the well-known link between adiposity in the abdominal region and the risk of development of various diseases, it is also associated with glucose intolerance and alterations in lipid profile. Furthermore, the adipocytes in this region are more resistance to lipolysis (LOBO, 2002; NEVES, 200; GODOY, 2002).

The most well-known and common treatments for localized fat are: maintaining a balanced diet, practicing physical activity, liposuction surgery, manual and mechanical lymphatic drainage (which deals with circulatory disorders involving a predisposition to accumulate fat in certain areas of the body), and in particular, a new method used by Dermato-functional Physiotherapy; the technique of Electrolipolysis, which consists of the application of a low-frequency, alternating electrical current that stimulates the physiological process of lipolysis in specific areas of the body (FARIA, 2007; GUIRRO; GUIRRO, 2002)

Electrolipolysis is defined as a technique for treating adiposities and accumulation of localized fatty acids. It consists of the application of a low-frequency microcurrent (around 25 Hz) that acts directly on the adipocytes and accumulated lipids, destroying and eliminating them. The electrical field that originates between the electrodes causes, at a local level, a series of physiological changes that are responsible for the phenomenon of lipolysis (BORGES, 2006; PARIENTI, 2001; MATOSO, 2008; GODOY, 2002; AGNE, 2008; GRAFF; ISAAC, 2004; ROSSI, 2002; ULRICH, 2000; SILVA, 2007; MATOSO, 2008). Thus, the objective of this study was to evaluate the effectiveness of the use of the technique of Electrolipolysis in reducing abdominal measurements.

METHODOLOGY

This is an exploratory study, with a descriptive approach, developed at the Clínica Escola Integrada of the Faculdade Santa Maria in the town of Cajazeiras – PB. Its subject is a patient, NGS, female, 27 years of age, a non-smoker, nulliparous, a nursing technician, sedentary, without endocrinal/metabolic alterations, not using oral contraceptives or other medications, not practising physical activity, and with irregular eating habits. Meeting the criteria for the objective of the research, she agreed to take part, by signing a Term of Free, Informed Consent. A Physiotherapeutic assessment form was used, and for the Physical Examination, Inspection, Palpation and Perimetry were carried out, using a metric tape and measuring the abdominal diameter (the umbilical scar was taken as the point of reference, then with a dermographic pen, two points were drawn, 3 cm above and below the umbilicus), as well as the saddlebag region of the thigh (under the gluteal fold) of the patient, for the purposes of comparison, at the time of assessment and at the end of treatment. The patient was submitted to 20 sessions of electrolipolysis, positioned in dorsal decubitus, with the lower limbs semi-flexed and relaxed, after demarcating and sterilizing (with 70% alcohol) the area to be treated, eight disposable 0.3 mm diameter acupuncture needles, 10 cm in length, were inserted into the abdomen region, spaced 5 cm apart. A model 110 c Electrolipolysis device was used, from Sikuro DS®. The parameters adopted were: Automatic polarity inversion mode, every 2.0 seconds, and frequency of 30 Hz. The intensity was determined by the patient's sensitivity and tolerance, and was increased as many times as necessary after the accommodation process. Each application lasted 50 minutes, with frequency of two applications per week. To measure the thickness of the Subcutaneous Cellular Tissue (SCCT) before and after treatment, Ultrasound exams were carried out on the soft tissues of the abdomen, with a Voluson 730 PRO Ultrasound Machine, with 5.0 Mhz linear transducer at 13 Mhz. The data were presented in the form of tables, to facilitating their reading.

RESULTS AND DISCUSSIONS

The data relating to this research were collected through the results of the patient of this case study, based on the proposed questionnaire, and were analyzed and presented in the form of tables, photographic images, and Ultrasound exam.

Table 1. Description of the abdominal perimetry measurements before and after Electrolipolysis treatment, expressed in cm.

Anatomical Point	Measurements Before	*Measurements After*
Supraumbilical Region (3 cm above the umbilical scar)	**81**	***76***
Infraumbilical Region (3 cm below the umbilical scar)	**95**	***87***
Saddlebag (below the gluteal fold)	**95**	***95***

Table 1 shows the decrease in abdominal circumference, of 5 cm in the supraumbilical region and 8 cm in the infraumbilical region. The hip measurement remained unchanged, at 95 cm, as no intervention was carried out at this site. These findings corroborate those described by Robinson; Snyder (2001), who states that electrical stimulation is capable of activating a local reaction of lipolysis, by causing an increase in blood glycerol and free fatty acids. According to the same authors, this occurs due to the mediation of the catecholamines, as when a beta-blocking agent is administered, a significant reduction is observed in the extent of the phenomenon.

Table 2. Body Weight before and after Electrolipolysis, expressed in Kg.

BODY WEIGHT	
BEFORE	*AFTER*
59.9	*59.6*

Table 2 shows that in general, there was no loss of body weight, which remained practically the same before and after treatment. There was a reduction of just 300g in body weight, a value that could not have affected the reduction in measurements. The lipolytic action of electrostimulation is localized, i.e. it is concentrated in the region that receives the stimulus of the current, starting with the stimulation of the sympathetic nervous system, where the two main lipolytic enzymes HSL (Hormone-sensitive Lipase) and LPL (lipoprotein lipase) act inside the adipocytes and triglyceride (TG)-rich lipoproteins (GUYTON; HALL, 2001).

Table 3. Ultrasound of the Soft tissues carried out before and after Electrolipolysis treatment (Biometry of the thickness of the subcutaneous layer).

Ultrasound of the Soft Tissues of the Abdomen	Before	*After*
Supraumbilical region (right)	3.93	3.78
Supraumbilical region (left)	3.77	3.77
Infraumbilical region (right)	5.18	4.17
Infraumbilical region (left)	4.87	4.01
Right Flank Region (at the level of the umbilicus)	1.90	1.56
Left Flank Region (at the level of the umbilicus)	1.82	1.72
Right Lateral Region (at the level of the umbilicus)	4.64	4.55
Left Lateral Region (at the level of the umbilicus)	4.96	4.56

Table 3 shows that there was a significant decrease in thickness of the Subcutaneous Tissue, observed in the Ultrasound Exam, particularly in the right infraumbilical region (Before 5.18, After 4.17). The skin is the most extensive sensory organ of the body, receiving tactile, thermal and pain stimuli. Its water content is around 70% of the weight of the skin, not including the adipose tissue, containing nearly 20% of the total water content of the organism. It is around 0.5 to 4 millimeters in thickness, and is therefore the most sensitive of our organs, our first means of communication, and our most efficient protector, as it is our first and last line of defense (ARAÚJO, et al, 2007; GUIRRO; GUIRRO, 2002)

BEFORE

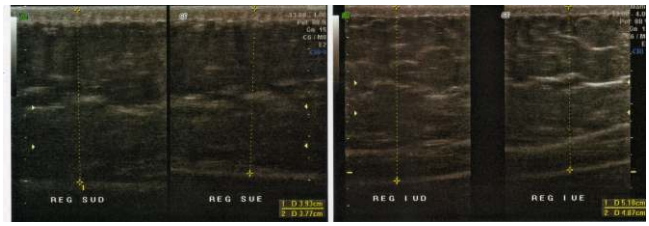

Right Supraumbilical Region 3.93 cm **Right Infraumbilical region 5.18 cm**
Left Supraumbilical Region 3.77cm **Left Infraumbilical Region 4.87 cm**

Figure 3: Images of the Ultrasound Exam before treatment of the right and left Supra- and Infraumbilical regions.

AFTER

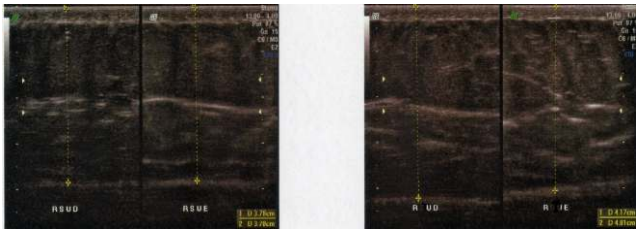

Right Supraumbilical Region 3.78 **Right Infraumbilical region 4.17**
Right Supraumbilical Region 3.77 **Left Infraumbilical Region 4.01**

Figure 4. Images of the Ultrasound before treatment of the right and left Supra- and Infraumbilical regions.

Figure 4 shows the results of the Ultrasound exams in the four quadrants of the abdomen. A statistically significant difference was found between the values before and after the intervention, as shown in table 3. There was a significant decrease in the infra- and supraumbilical regions, both right and left. In the right supraumbilical region, there was a reduction of 1.5 mm; in the right infraumbilical region the difference was 10.1 mm; and in the left infraumbilical region, the difference was 8.6 mm. These data corroborate those of the literature, for example Garcia, Garcia and Borges (2006), who describe continued, prolonged effects over the weeks following the application, for at least 45 days after the end of the treatment.

The circulatory stimulus produce by the currents is of great importance for draining the area and stimulating lipolysis, whether directly or indirectly, through excitation of the sympathetic nerve endings and the release of catecholamines (adrenaline and noradrenalin), which act on the adipocyte receptors and stimulate the enzyme that potentializes the lipolysis of the triglycerides into glycerol and fatty acids (ASSIS, et al, 2008). Owing to the joule effect, the electrical stimulation causes physiological changes in the adipocyte. The increase in temperature that is produced in electrolipolysis contributes to the installation of a vasodilator, with the increase in local blood flow. This study is similar to the reports of other authors, like Araújo et

al, 2007 and Parienti, 2001 who report that through electrical stimulation, it is possible to activate lipolysis. This is the function of the joule effect, a process of burning fat, via thermal energy, the body itself being a good conductor. Histopathological studies demonstrate the effect of this treatment on the adipocytes (decrease in size, alterations shape and structural changes) (BARACAT, et al, 2004; GOUVEIA, 2002).

FINAL CONSIDERATIONS

Through the results obtained, it was found that the technique of Electrolipolysis is successful in the treatment of localized lipodystrophy. However, further studies on the subject are necessary, whether with Electrolipolysis alone, or in association with other resources and techniques.

REFERENCES

1. AGNE, J.E. Eletrotermoterapia: Teoria e Prática. 1. ed. Santa Maria: Orium, 2008.

2.ARAÚJO, C.P.; BRITO, A.K.A.T.; ESCARIÃO, A.D.; TORRES, R.B. A Eletrolipólise como método de redução de adiposidade no abdome inferior: estudo piloto. Revista de Especialização em Fisioterapia, V. 1, 2007.

3.ASSIS, A.C.M.; OLIVEIRA, M.P.; OLIVEIRA, S.G.; REIS, M.L.; BORGES, F.S. Uso da Eletrolipólise com Frquências de 25 Hz e 100 Hz na Redução da Gordura Localizada Abdominal Associada ao Controle da Ingestão Calórica. Revista Especialização Fisioterapia. Vol. 2 - nº 2. Universidade Gama Filho. Belo Horizonte: 2008.

4. BARACAT, E.C.; BARBOSA, I.C.; CAMPOS, A.A.; HYPPOLITO, S.B.; MELO, N.R.; MUSSIELO, R.; NASSAR, R.; NETO, J.S.P.; TOMAZ, G. Avaliação da Tolerabilidade e do Controle de Ciclo de Dois Contraceptivos Orais de Baixa Dose: Estudo Comparativo Aberto. RGBO 20 (5): 273-280, 2004.

5. BORGES, F.S. Dermato-Funcional: Modalidades Terapêuticas nas Disfunções Estéticas. 1. ed. São Paulo: Phorte, 2006.

6. FARIA, J. Lipoaspiração. Mitos e Realidade. 1.ed. Rio de Janeiro: Madras, 2007.

7. GARCIA, P.G., GARCIA F.G., BORGES, F.S. O Uso da Eletrolipólise na Correção de Assimetria no Contorno Corporal Pós-Lipoaspiração. Fisioterapia Ser 2006; v.1 n.4.

8. GODOY, S.C.A. Fisioterapia e Estética. 1. ed. Rio Claro: Orium, 2002.

9. GOUVEIA, V.V.; SINGELIS, T.M.; COELHO, J.A.P.M.; Escala de Auto-Imagem:

Comprovação da Sua Estrutura Fatorial. Universidade Federal da Paraíba. Universidade Federal da Califórnia. Avaliação Psicológica, 1: 2002.

10. GUIRRO, E.; GUIRRO, R. Fisioterapia Dermato-Funcional. 3. ed. São Paulo: Manole, 2002.

11. GUYTON, A.C.; HALL, J.E. Tratado de Fisiologia Médica. 9 ed. Rio de Janeiro: Guanabara Koogan, 2001.

12. GRAFF, D.; ISAAC, C. Eletrolipoforese. 1. ed. In: Maio, M. Tratado de Medicina Estética. São Paulo: Phorte, 2004.

13. LOBO, W. Lipodistrofia. 1. ed. São Paulo: Robe, 2002.

14.MATOSO, M. Fisioterapia Dermato-Funcional. Informando a Quem Busca Conhecimento em Saúde Estética. Eletrolipólise (Eletrolipoforese). 1. ed. São Paulo: Record, 2008.

15. NEVES, S.R.; OLIVEIRA, D. Eficácia da Associação de Técnicas Manuais e Eletrotermoterapia na Redução de Medidas do Abdome. Revista de Biologia e Saúde da UNISEP-ISSN: 1982-2774- Biology & Health Journal- v.1,n.1,2.2007.

16. PARIENTI, I.J. Medicina Estética. 1. ed. São Paulo: Andrei, 2001.

17. ROBINSON, A.J.; SNYDER, M.L. Eletrofisiologia Clínica: eletroterapia e teste eletrofisiológico. 2. ed. Porto Alegre: Artmed, 2001.

18. ROSSI, A.B.R. Lipodistrofia Ginóide: Aspectos Epidemiológicos, Clínicos, Histopatológicos e Terapêuticos. Revista Méd News. São Paulo, n 18, Dezembro, 2002.

19. SILVA, M.T. Eletroterapia em Estética Corporal. 1. ed. São Paulo: Robe, 2007.

20. ULRICH, W. A Celulite é Curável. 1. ed. Rio de Janeiro: Tecnoprint, 2000.

ELIANA NUNES DA SILVA:
Rua Júlio Pajeú, 41, Cristo Rei,
CEP: 58900-000,
Cajazeiras – PB.
E-mail: elianaserragrande@yahoo.com.br

ELECTROLIPOLYSIS IN THE REDUCTION OF ABDOMINAL MEASUREMENTS: A CASE STUDY

ABSTRACT

Introduction Electrolipolysis is a technique that is used to treat localized adiposities through the application of specific electrical currents that act directly on the accumulated adipocytes and lipids. Objectives: To determine the effectiveness electrolipolysis applied with needles, for the treatment of localized adiposities in the abdominal region. Material and methods: According to resolution no. 196/96 of the National health Council. The sample consisted of a female patient, aged 27 years, a student, nulliparous, a non-smoker, sedentary, not submitted any high calorie diet, not using oral contraceptives or other medications, without endocrinal/metabolic alterations, and with irregular eating habits. First the following were carried out: Physiotherapeutic assessment, Perimetry measurements and Ultrasonography of the Soft Tissues in the area of the Abdomen. The patient was submitted to 20 sessions. An Electrolipolysis device was used, with the following parameters: 4 pairs of needles, frequency of 30 Hz, 50 min and intensity according to the patient's sensitivity, and with periods of accommodation. Results: In the perimetry measurements, there was a loss of 5 cm in the supraumbilical region and 8 cm in infraumbilical region. In the imaging exam, there was a reduction in the fat layer, particularly in the infraumbilical region (10.1mm). The weight remained unaltered. Conclusion: The study shows that Electrolipolysis is indeed an effective method for reducing localized fat.

KEY WORDS: Lipolysis. Electrical Stimulation Therapy. Measurements.

ÉLECTROLIPOLYSE RÉDUCTION DES MESURES ABDOMINALE: UNE ETUDE DE CASE

SOMMAIRE

Introduction: La électrolipolyse est une technique destinée au traitement des adiposités localisées, en émettant des courants d'électricité qui agissent directement au niveau des adipocytes et des lipides accumulés. Objectifs: Vérifier l'efficacité de l'utilisation de l'électrolipolyse en appliquant de aiguilles dans le traitement de adiposités localisées à la région abdominal. Matériaux et Méthode : La résolution nº 196/96 du Conseil National de Santé a été adoptée. L'échantillon a été une patient de 27 ans, étudiante, nullipare, non fumeuse, sédentaire, non soumise à aucun régime hypocalorique, non utilisatrice de contraceptifs

oraux ou d'autres médicaments, sans alterations endocrino/métaboliques et avec de habits alimentaires irréguliers. En premier on a effectué : Évaluation physiothérapeutique, Mesures périmétriques, et Ultrasonographie des tissus mous à la région abdominal. La patient a été soumise à 20 sessions. On a utilisé un appareil d'électrolipolyse avec les paramètres suivants : 4 pairs d'aiguilles, une fréquence de 30 Hz., 50 min. et une intensité par rapport à la sensibilité de la patient et avec les périodes d'adaptation. Résultats : Au périmètres, il y a eu une perte de 5 cm. à la région sus-ombilical et 8 cm. à la région sous-ombilical. À l'examen d'une image il y a eu une réduction de la couche de la graisse, surtout à la région sous-ombilical (10.1 mm.) Le poids de la patient est resté inaltéré. Conclusion : Cet étude a démontré que l'électrolipolyse est en fait une méthode eficace pour la réduction de la graisse localisée.

MOTS-CLÉS: la lipolyse. Traitement par stimulation électrique. Mesures.

ELECTROLIPÓLISIS EN LA REDUCCIÓN DE MEDIDAS ABDOMINAL: UN ESTUDIO DE CASO

RESUMEN

Introducción: La electrolipólisis es una técnica destinada al tratamiento de adiposidades localizadas, con aplicación de corrientes eléctricas específicas que actúan directamente a nivel de los adipocitos y de los lípidos acumulados. Objetivos: Verificar la efectividad del uso de la electrolipólisis aplicando agujas en el tratamiento de adiposidades localizadas en la región abdominal. Materiales y Métodos: Fue adoptada la resolución nº 196/96 del Consejo Nacional de Salud. La muestra fue compuesta por una paciente de 27 años, estudiante, nulípara, no fumadora, sedentaria, sin someterse a ninguna dieta hipocalórica, no usuaria de anticonceptivos orales u otros medicamentos, sin alteraciones endócrino/metabólicas y con hábitos alimenticios irregulares. Primeramente fueron realizadas: Evaluación fisioterapéutica, Medidas perimétricas y Ultra-sonografía de tejidos blandos en la región del abdomen. La paciente fue sometida a 20 sesiones. Fue utilizado un aparato de electrolipólisis en los siguientes parámetros: 4 pares de agujas, frecuencia de 30 Hz., 50 min. e intensidad de acuerdo a la sensibilidad de la paciente y a los periodos de adaptación. Resultados: En los perímetros hubo pérdida de 5 cm. en la región supraumbilical y de 8 cm. en la región infraumbilical. En el examen de imagen hubo una reducción de la capa de obesidad, principalmente en la región infraumbilical (10.1 mm.). El peso se mantuvo sin alteración. Conclusión: El estudio demostró que la electrolipólisis es un método realmente eficaz en la reducción de gordura localizada.

PALABRAS CLAVE: la lipólisis. Terapia de estimulación eléctrica. Medidas.

ELETROLIPÓLISE NA REDUÇÃO DE MEDIDAS ABDOMINAIS: UM ESTUDO DE CASO

RESUMO

Introdução A eletrolipólise é uma técnica destinada ao tratamento das adiposidades localizadas, com aplicação de correntes elétricas específicas que atuam diretamente ao nível dos adipócitos e dos lipídeos acumulados. Objetivos: Verificar a eficácia da utilização da eletrolipólise no modo de aplicação com agulhas no tratamento de adiposidades localizadas na região abdominal. Materiais e Métodos: De acordo com a resolução nº 196/96 do Conselho Nacional de Saúde. A amostra foi composta por uma paciente de 27 anos, estudante, nulípara, não tabagista, sedentária, não submetida a nenhuma dieta hipocalórica, não usuária de contraceptivos orais ou outros medicamentos, sem alterações endócrino/metabólicas e com hábitos alimentares irregulares. Primeiramente foram realizadas: Avaliação Fisioterapêutica, Medidas de Perimetria e Ultra-Sonografia de Tecidos Moles na Região do Abdômen. A paciente foi submetida a 20 sessões. Foi utilizado aparelho de Eletrolipólise nos seguintes parâmetros: 4 pares de agulhas, freqüência de 30 Hz, 50 min e intensidade de acordo com a sensibilidade da paciente e com os períodos de acomodação. Resultados: Na perimetria, houve perda de 5 cm na região supra-umbilical e 8 cm na região infra-umbilical. No exame de imagem houve uma redução da camada de gordura, principalmente na região infra-umbilical (10,1mm). O peso manteve-se inalterado. Conclusão: O estudo demonstrou que a Eletrolipólise é um método realmente eficaz na redução da gordura localizada.

PALAVRAS-CHAVE: Lipólise. Terapia por Estimulação Elétrica. Medidas.