29 - TRANSFEMORAL AMPUTATION: MAJOR COMPLICATIONS IN PRE PROSTHESIS

ANDRÉIA GOMES HOGAHA
JOSÉ MOHAMUD VILAGRA
Faculdade Assis Gurgacz- FAG, Cascavel, PR - BRASIL,
deianeusa@hotmail.com

INTRODUCTION

Amputation is often feared by all, it brings the image of mutilation, disability, inability to work and perform their activities in daily living. Those consequences are feared by individuals who will suffer an amputation (Boccolini, 2000).

According to Carvalho (2003), amputation is a word derived from Latin, with the meaning: partial or total withdrawal of one or more limbs. The amputation of limbs may occur for etiologies of processes vascular, neuropathic, traumatic, tumor, infectious and congenital, for example hypertension, high cholesterol, triglycerides and smoking.

Fernandes (2007), says that diabetic patients with peripheral neuropathy is a progressive loss of tactile and propriopceptiva. This leads to an increased risk of formation of calluses, sores and infections. When there is infection with decreased blood flow, gangrene may occur if treatment is ineffective, the patient will have to amputate the site. With the progression of the disease, there is involvement of large arteries, with atherosclerotic framework, this can happen to ischemia, causing the level of transfemoral amputation is higher. Healing is higher, but there is greater difficulty walking with prosthesis.

Peripheral neuropathy also can now be considered as a cause for amputation. Several diseases or processes can lead to peripheral neuropathy such as diabetes mellitus, a nutritional disorder, like alcoholism, infectious diseases, such as Hansen and Poli, spinal cord changes, such as spina bifida and spinal cord trauma. Intermittent claudication and loss of distal pulses are classic symptoms of arterial insufficiency, which could also lead to limb amputation. (CARVALHO, 2003).

The types of amputation of lower limbs are: partial foot amputation, Syme, transtibial, knee disarticulation, transfemoral, hip disarticulation and hemipelvictomia (BOCCOLINI, 2000). The transfemoral amputation refers to any amputation performed between the knee and hip (CALMELS et al, 2001 and CARVALHO, 2003 apud BARAUNA et al, 2006). Can be divided into three levels, ie, transfemoral amputation in the proximal, middle and distal (BOCCOLINI, 2000).

According to Carvalho (2003) the stump is responsible for controlling the prosthesis during the standing and walking. To make this possible, he should show some characteristics such as adequate, stable stump, presence of a good cushion with myoplasty and miodese, good skin, absence of terminal neuromas and bone fragments, good arterial circulation and venous good healing and no significant edema.

The amputee has significant implications sensory loses sensory information from the skin, joints, tendons and muscles. If the muscles are not reinstated on the bone end with a length / tension normal, the information of the central nervous system is wrong as well as reduced, interfering with the central excitatory state and therefore the motor control (LIANZA, 2001).

The objective of prosthesis is to restore the patient to a normal life and integrate it into society, allowing its movement through the prosthesis, entering a greater role in their activities of daily living and professional while holding in a better quality of life (SAMPOL , 1997).

The earlier initiation of rehabilitation, the greater the potential for success and the more delayed the start, there will be more likely to develop secondary complications such as joint stiffness, general debilitation and psychological state depressed.

The sooner the implant is placed, the better for the amputee. One of the most difficult of the amputee is edema, or swelling of the stump, due to the accumulation of fluids. Edema is present to some extent, in all cases, and this makes the placement of the prosthesis is difficult, but certain measures can be taken to reduce the amount of edema. (CARVALHO, 2003).

And, according to Friedmann (1994) quoted Brito (2005), the main causes of complications in the amputation stump are swelling, sutures, phantom pain, stump ulceration, inflammation, infections, scar retraction, bone spurs, and neuromas.

These types of problems often affect the stump of the second to third week after surgery. The problems arising from causes such as neuromas, contractures and muscle atrophy, among others, occur later, although the pain can occur at any time, with features the most diverse (O'SULLIVAN, 1993).

To Koury (2000) there are many variables that complicate the recovery process, as the degree of injury, type of surgical procedure used, the fitness level of the patient before the injury or surgery, the time lapse between injury or surgery and physical therapy, physical therapy resources and individual physiological and psychological factors that affect the healing process (nutrition, stress, smoking and commitment), the rate of progress and overall success of treatment will be different for each individual.

The analysis of the stump is in the process outpatient. The surgical scar should be examined, noting whether it is with or without grip, and how the scar looks: terminal, anterior, posterior or if there is another type of retail.

MATERIALS AND METHODS

The present research it is a field study, epidemiological, quantitative cross-sectional, where the sample consisted of 20 subjects, 5 females and 15 males, aged between 19 and 84 years. For inclusion, all patients had to have the type transfemoral amputation, regardless of sex and that they had never used prosthesis. The participants interviewed were conducting follow-up or physical therapy at the Rehabilitation Center of Assisi School Gurgacz-FAG, located in the city of Cascavel - PR.

Was used as a research tool to a questionnaire containing 23 questions, created by the researchers with questions related to complications of post-fitting, where they were questioned individually each patient, between the period April to June of 2009. To analyze the results and create graphs to present data, we used the Microsoft Excel 2003.

RESULTS AND DISCUSSION

Physiotherapy is a science that studies health, prevents and treats the kinetic functional disorders, in organs and body systems, generated by genetic trauma and acquired diseases. The physical therapists can work in various areas such as Orthopedics and Traumatology, Rheumatology, Obstetrics and Gynecology, Pulmonology, Cardiology, Neurology, Physical Therapy Sports, among others.

According to Carvalho (1999), amputation is located in the area of Orthopedics and Traumatology, and is considered

as old as humanity itself, where they have the knowledge is to be performed thousands of years, as the oldest of all surgical procedures .

One of the main complications in amputation and not responsible for the use of the prosthesis in transfemoral amputees is the phantom pain, defined as a chronic pain in the missing member. Patients complain of pain in cramps, burning or stabbing (FERNANDES, 2007).

This phantom pain should be produced by the absence of nerve impulses from the State. When a nerve is cut, produces a violent discharge of the lesions in all types of fibers. This excitation decreases rapidly and sectioned nerve becomes silent, until new nerve endings start to grow. This implies that the central nervous system (CNS) accounts for the lack of normal inflow, so, some amputees have so little pain or feel the pain so sporadically, they deny it suffers from phantom limb pain, whereas others suffer pain with greater frequency . (Debastiani, 2005).

Of the items identified in the literature analyzed in this study as possible factors that determine or contribute to the presence of phantom pain, which was the major complication identified in the research, found that only the type of scar classified as terminal, correlated with the phantom pain for transfemoral amputees in this sample, as can be seen in the chart below:

CHART 1: Correlation of the type of scar and the incidence of phantom pain

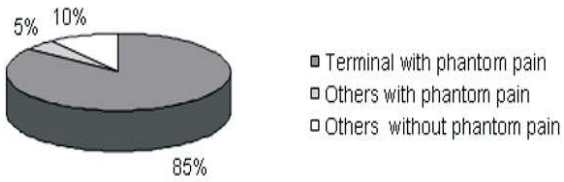

Source: The author, 2009

Chart 2 shows the types of scar presented in transfemoral amputees. The percentage of people who have scar classified as terminal is 85%, as those with other types of scar represent 15%, noting that other type of scarring, is not included those classified as anterior or posterior.

CHART 2: Type of scar

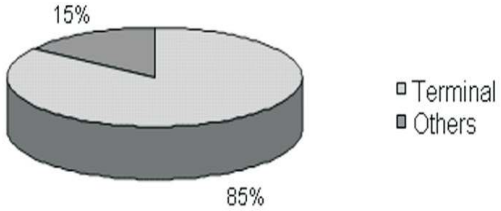

Source: The author, 2009.

While maintaining the highest length possible to be recommended for amputation-section through the femur, relative to the level of amputation 70% of the subjects of this study have amputation in the medial third, and 30% in the proximal third, none in the distal third or disarticulation knee.

CHART 3: Level of amputation

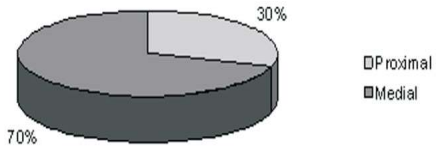

Source: The author, 2009.

CONCLUSION

The physiotherapist plays a key role in the rehabilitation of lower limb amputees, and the early initiation of appropriate treatment can influence the results of any rehabilitation, noting that amputation should be considered not as the end of something, but the beginning of a new phase.

Based on the findings of this study it can be said that the type of surgical flap is one factor that contributes to divisible incidence of phantom pain in transfemoral amputees. But in research conducted in the available literature, there are few studies involving these variables.

This research contributes to the odd preventive action in patients with transfemoral amputation. By identifying this factor will enable a targeted intervention to minimize the compromise, change in surgical procedures or even to studies, clinical trials to consider the variables identified in this study.

REFERÊNCIAS

BARAÚNA, et.al, Avaliação do equilíbrio estático em indivíduos amputados de membros inferiores através da biofotogrametria computadorizada. Revista Brasileira de fisioterapia , 2006.

BOCOLINI, F. Reabilitação - Amputados, Amputações e Próteses. 2. ed., São Paulo: Robe, 2000.

CARVALHO, J. A. Amputações de Membros Inferiores em busca de Plena Reabilitação. 1. ed. São Paulo: Manole, 1999.

_____. Amputações de membros inferiores. 2. ed., São Paulo: Manole, 2003.

CALMELS, P. et.al. Échellees d´evaluation fonctionnelle et amputation du membre inférieur. Ann Réadaptation Méd Phys, 2001 disponível em : <http://www.sciencedirect.com/science?_ob=MImg&_imagekey=B6VKC-44HS9N0-1-2&_cdi=6119&_user=687375&_orig=search&_coverDate=11%2F30%2F2001&_sk=999559991&view=c&wchp=dGLbVlb-zSkzk&md5=ffb17256d629a6a91d957988b34caf99&ie=/sdarticle.pdf> Acesso em 20 Ago. 09.

DEBASTIANI, J.C. Avaliação do equilíbrio e funcionalidade de indivíduos amputados de membro inferior protetizados e reabilitados. 2005. Dissertação (Bacharel em Fisioterapia)-Universidade Estadual do Oeste do Paraná,Cascavel.

FERNANDES, A; RAMOS, A; CASALIS, M; HEBERT, S. AACD: Medicina e Reabilitação Princípios e Prática. s/ed..São Paulo:Artes Médicas Ltda,2007 .

FRIEDMANN, L. W. Reabilitação do amputado de membro inferior. Tratado de medicina física e reabilitação de Krusen. 4. ed.São Paulo: Manole, 1994.

LIANZA, S. Medicina de reabilitação. 3.ed.Rio de Janeiro: Guanabara Koogan, 2001.

O´SULLIVAN, S. SCHIMITZ, J.T Fisioterapia – Avaliação e tratamento. 2ed., São Paulo, Manole:1993.

SAMPOL, V.A A protetização no membro inferior. Revista Fisio&Terapia. n.5. Out/Nov 2007, disponível em HTTP://www.vitalsampol.com.br/artigos/artigo16-30/artigo19.html Acesso em 27 Ago, 2009.

Nome: Andréia Gomes Hogaha.
Endereço: Rua Antonio Damian, 538.
Jardim novo milênio, Cascavel - PR
Telefone: 45.3326-8357 ou 45.9923-6669
deianeusa@hotmail.com

TRANSFEMORAL AMPUTATION: MAJOR COMPLICATIONS IN PRE PROSTHESIS

ABSTRACT

The term amputation has the meaning of the partial or total withdrawal of one or more limbs. This research was developed at the Rehabilitation Center of Assis Gurgacz College-FAG, where 20 individuals with transfemoral amputation were interviewed, aged between 19-84 years, who were conducting monitoring or rehabilitation. This is a field study, epidemiological, quantitative cross-sectional. Its main objective was to identify the major complications during the pre-fitting. As instrument, it was used a questionnaire with 23 questions, applied between the months of April to June 2009, where we were able to identify the major complications found after amputation. After collecting the data, it was found that phantom pain was one of the most common among the major complications, and more than half of the questioned people reported the change, and related to the type of scarring resulting from the surgical process. All respondents who had phantom pain were welcomed with amputation, therefore the presence of phantom pain in the sample studied, has no correlation with the acceptance because this is an emotional factor. It was also observed that the banding was not a factor that showed a direct relation with the phantom pain.

KEYWORDS: pre-fitting, transfemoral amputation, complications.

AMPUTATION TRANSFÉMORALE: PRINCIPALES COMPLICATIONS AVANT LA PROTHETISATION

RÉSUMÉ

Le mot amputation signifie une coupe totalle ou partielle d'un ou des plusieurs membres du corps. Cette recherche a été développée au Centre de Réadaptation De la faculté Assis Gurgacz - FAG, où nous avons interviewé 20 personnes avec amputation transfémoral, âgés de 19 à 84 ans, qui effectuaient accompgnement ou la réadaptation. Il s'agit d'une étude de champ, épidémiologique, quantitative, de coupe transversal. L'objectif a été identifier les principales complications avant la prothetisation. A été utilisé comme un instrument, un questionnaire comportant 23 questions, appliqué entre les mois d'avril à Juin 2009, où a été possible d'identifier les principales complications trouvées après l'amputation. Après la collecte de données, il a été constaté que la douleur fantôme s'est evidenciée parmi les principales complications, et plus de la moitié des personnes interrogées ont signalé le changement, et l'a relationée avec le type de cicatrisation résultant du processus chirurgical. Tous les interviewés qui avaient des douleurs fantômes ont bien accepté l'amputation, donc, la présence de douleur fantôme dans l'échantillon étudié, ne présente aucune corrélation avec l'acceptation, que s'agit d'un facteur émotionnel. Il a également été observé que l'émmaillotement n'a pas été un facteur qui a montré une relation directe avec la douleur fantôme.

MOTS-CLÉS: l'amputation transfémoral, complications, prothetisation.

AMPUTACIÓN TRANSFEMORAL: PRINCIPALES COMPLICACIONES EN LA PREPROTETIZACIÓN

RESUMEN

El término amputación tiene como significado la retirada total o parcial de uno o más miembros del cuerpo. La presente investigación fue desarrollada en el Centro de Rehabilitación de la Facultad Assis Gurgacz-FAG, donde fueron entrevistados 20 individuos portadores de amputación transfemoral, con edad entre 19-84 años, que estaban realizando acompañamiento o rehabilitación. Se trata de un estudio de campo, epidemiológico, cuantitativo, de corte transversal. Tuvo como objetivo identificar las principales complicaciones durante la preprotetización. Se utilizó como instrumento, un cuestionario con 23 cuestiones, aplicadas entre los meses de abril a junio de 2009, donde se pudo identificar las principales complicaciones encontradas después de la amputación. Después de la coleta de datos, se verificó que el dolor fantasma se destacó entre las principales complicaciones, siendo que más de la mitad de la población cuestionada relató la alteración, y la relacionó con el tipo de cicatrización decurrente del proceso quirúrgico. Todos los entrevistados que presentaron dolor fantasma tuvieron buena aceptación con la amputación, por lo tanto, la presencia del dolor fantasma para la muestra estudiada, no presenta correlación con la aceptación, que se trata de una causa emocional. Se observó también que el fajamiento no fue una causa que presentó relación directa con el dolor fantasma.

PALABRAS-CLAVE: Preprotetización, amputación transfemoral, complicaciones.

AMPUTAÇÃO TRANSFEMORAL: PRINCIPAIS COMPLICAÇÕES NA PRÉ PROTETIZAÇÃO

RESUMO

O termo amputação tem como significado a retirada total ou parcial de um ou mais membros do corpo. A presente pesquisa foi desenvolvida no Centro de Reabilitação da Faculdade Assis Gurgacz-FAG, onde foram entrevistados 20 indivíduos portadores de amputação transfemoral, com idade entre 19-84 anos, que estavam realizando acompanhamento ou reabilitação. Trata-se de um estudo de campo, epidemiológico, quantitativo, de corte transversal. Teve como objetivo identificar as principais complicações durante a pré-protetização. Utilizou-se como instrumento, um questionário com 23 questões, aplicadas entre os meses de abril a junho de 2009, onde pôde-se identificar as principais complicações encontrados após amputação. Após a coleta de dados, verificou-se que a dor fantasma destacou-se entre as principais complicações, sendo que mais da metade da população questionada relatou a alteração, e a relacionou com o tipo de cicatrização decorrente do processo cirúrgico. Todos os entrevistados que apresentaram dor fantasma tiveram boa aceitação com a amputação, portanto, a presença de dor fantasma para a amostra estudada, não apresenta correlação com a aceitação, que trata-se de um fator emocional. Observou-se também que o enfaixamento não foi um fator que apresentou relação direta com a dor fantasma.

PALAVRAS-CHAVE: pré-protetização, amputação transfemoral, complicações.

PUBLICAÇÃO NO FIEP BULLETIN ON-LINE: http://www.fiepbulletin.net/80/a2/29