# 220 - FOURNIER'S SYNDROME: USUAL CURATIVE X CURATIVE WITH HONEY ASSOCIATED WITH DRUG THERAPY, SÃO PAULO, SP, 2005 TO 2007.

MARIA JOSÉ BARBOSA;
ROBSON MIRANDA DA GAMA;
REGINA SIQUEIRA HADDAD CARVALHO.
Universidade de Santo Amaro - Faculdade de Farmácia, São Paulo-SP, Brasil.
barbosa.lika@gmail.com, reginash@gmail.com

**INTRODUCTION**

Fournier's syndrome was described in the literature for the first time in 1883 by Jean Alfred Fournier, a French venerologist, who reported the syndrome as an acute process with progressive and rapid evolution to idiopathic gangrene in the scrotal area of healthy young men (BORRELLI, 1985; EKE, 2000; HERING, 1998).

Nowadays Fournier's syndrome is a rare disease that starts with an infection and necrotizing subcutaneous tissue and may have different origins such as urogenital, anorectal and skin were due to diseases arising from those involved regions. (ARRUDA, 1999; LIRA et al., 1998; SOBRADO et al., 1997).

The source of infection is described by many authors as diseases related to urogenital and perianal region. Some authors emphasize that the onset of the infection can be due to urethral strictures, traumatic catheterization, urethral calculus, transrectal prostatic biopsy or infection of the periurethral glands (ARRUDA, 1999; BORRELLI, 1985, CARDOSO, FÉRES, 2007; GURDAL et al., 2003).

With regards to the anal region, the disease may be subsequent to an ischiorectal or perianal abscess secondary to a biopsy of rectal mucosa or a hemorrhoidal ligation or drainage of perianal abscess (ARRUDA, 1999; CARDOSO, FÉRES, 2007).

The cases of Fournier's gangrene with focus on skin are rare however they can take place. The infection can be post-trauma and post-elective surgeries such as vasectomy, penile prosthesis placement, orchiectomy and/or herniorraphy (ARRUDA, 1999).

Men are the most affected by Fournier's syndrome, and most are elderly (BORRELLI, 1985). Women appear in smaller numbers, being the origin due to abscesses in Bartholin's glands (ARRUDA, 1999). Although cases of children may occur, it appears in smaller numbers with fulminant clinical pictures (ALMEIDA, HILGERT, 2005; COSTA et al., 2004; ZANELLI et al., 1991).

The infection is polymicrobial and caused by synergism between bacteria. The organisms isolated from tissues and secretions were: Escherichia coli, Bacteroides fragilis, Streptococcus pyogenes, Staphylococcus aureus, Clostridium perfringens and Candida albicans (ARRUDA, 1999, COSTA et al., 2004; HERING, 1998; IMAD et al., 2004).

The mortality rate is high, especially in cases of diabetic, alcoholic and immuno-compromised patients once these factors associated with Fournier's syndrome increase the aggressiveness of the infectious process and may lead patients to death (CAPELLUNCHNIK, CHIA-BIN, KLUG, 1992; CARDOSO, FÉRES, 2007; NISBET, THOMPSON, 2002).

Fournier's syndrome begins with an infectious and necrotizing process of the fascia, reaching the subcutaneous and/or skin tissues of the urogenital and perianal region and may spread to other areas, because there is close relationship between the superficial and deep fascia, such as Colles (perineum) that communicates with the Buck (scrotum) and DART (penis) and may extend to Scarpa (abdomen) and tin (the lower abdomen) (ALMEIDA, HILGERT, 2005; NADAL et al., 1992).

Signs and symptoms are pain, swelling, erythema, crackle and tissue necrosis of the fascia. In some cases appears later part of fever and purulent secretion foul-smelling abscess has formed in the initial (ALMEIDA, HILGERT, 2005; ARRUDA, 1999; BORRELLI, 1985; HERING, 1998).

The treatment is based on the stabilization of the patient, surgical debridement with drainage of the involved area and administration of broad-spectrum antibiotics - a third-generation cephalosporin or penicillin and an aminoglycoside or metronidazole for anaerobes. The site curative is essential after debridement to remove pus and fibrin tissue, then aiding in the healing process (ALMEIDA, HILGERT, 2005; ARRUDA, 1999; HEJASE et al., 1996).

The derivation of urine (cystostomy) and fecal derivation (colostomy) are performed to reduce the focus of infection since many of the microorganisms are from the microbiota of these elimination pathways (CAPELHUCHNIK, CHIA-BIN, KLUG, 1992; HEJASE et al., 1996).

For patients who remain with toxemia after debridement, if myonecrosis is present due to infection by anaerobic, the treatment indicated is an adjuvant therapy with hyperbaric oxygen (HBOT), because anaerobes are killed in oxygen tensions above 4 mmHg (ARRUDA, 1999; HEJASE et al., 1996; LIMA et al., 2003; NADAL et al., 1992; STEINMAN et al., 1992). HBOT is accepted and approved by the Regional Council of Medicine of the State of Sao Paulo in the Resolution CRMESP 58/95 of 1995. It is the inhalation of 100% oxygen at a pressure that is higher than the atmospheric conditions at the sea level (760 mmHg) which is obtained inside sealed compartments (IAZZETTI, MANTOVANI, 1998; LIMA et al., 2003).

Since the HBOT is expensive and difficult to access in public hospitals, patients are treated with antibiotics, so the patient stays in the hospital is enlarged, encouraging cross infection and leading to the selection of pathogens resistant to these antibiotics.

Many authors indicate the curative with honey on the site. This adjuvant treatment has proved to be effective in helping swelling and inflammation control, death of pathogenic bacteria, debridement of necrotic spots and better wound curative (ALVES et al., 2008; ARRUDA, 1999; FERREIRA et al., 2003; GUARDAL et al., 2003). This is not true in Brazil, though.

The honey, a bee product, is a viscous, aromatic and sugar substance that is obtained from the nectar of the beet exudates produced by honeybees. Its aroma, taste, color, viscosity and medicinal properties vary with the type of flowering and specie of bees that produce it (MIORIN, 2002; MOREIRA, 2001; PEREIRA et al., 2003; WIESE, 2000).

The antimicrobial activity is given by physical factors such as hydrogen peroxide, high osmolarity, acidity (pH 3.6) which are responsible for inhibiting the growth of many species of microorganisms. Enzymes as invertase, diastase, glucose oxidase, catalase and phosphatase are responsible for digest the necrotic tissue. The chemical factors are related to the presence of volatile substances such as flavonoids, which are responsible for the antibacterial, anti-inflammatory and healing actions (MOREIRA, 2001; PEREIRA et al., 2003).

From various scientific studies we can observe the growth of apitherapy, whose benefits to human health have been considered by a growing number of professionals in the health area (MIORIN, 2002; PEREIRA et al., 2003). Beyond this, the

question of antimicrobial resistance is increasing and the use of antimicrobial drugs in the future is uncertain. Actions to reduce this serious risk must be taken, such as investing on research and curbing the indiscriminate use of antibiotics.

**OBJECTIVES**

**General Purpose**

Raising and monitoring cases of patients affected by Fournier's syndrome in a Public Hospital in the southern region of Sao Paulo over two years (2005 to 2007).

**Specific Objective**

Check the therapeutic activity of honey as an adjunct to curatives associated with drug treatment.

**MATERIALS AND METHODS**

The study is exploratory, descriptive and interpretive based on medical records of patients affected by Fournier's syndrome who were treated at a hospital in Sao Paulo, Brazil from March 2005 to February 2007.

The following variables have been analyzed: the origins and causes of disease, commonly associated diseases, surgical procedures, local therapy, antibiotic use and length of hospitalization.

**RESULTS AND DISCUSSION**

Of the eight patients treated between March 2005 and February 2007, all were male, from 38 to 76 years age, with different types of abscesses, being the scrotal abscess the most frequent one (Figure 1).

Six patients (75%) have presented associated diseases such as diabetes, hypertension, heart failure, colon cancer, deep vein thrombosis, smoking and alcoholism (Figure 2).

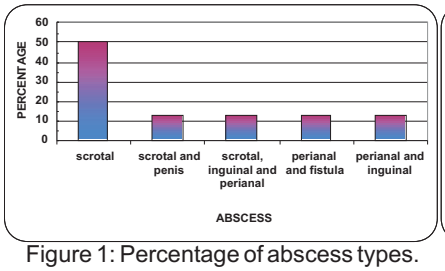


Figure 1: Percentage of abscess types.

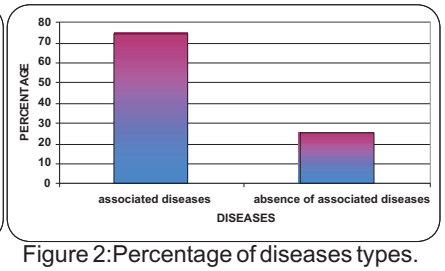


Figure 2:Percentage of diseases types.

Cystostomy plus one to two debridements have been performed in eight patients (100%). colostomy has been performed in two patients once the focus has been perianal and/or due to the extent of infection.

The length of hospital staying ranged from 17 to 53 days and one of the patients have died due to complications of associated diseases.

From the eight treated patients, half of them have received antibiotics associated with normal curatives and the others have received antibiotic therapy associated with curatives with honey. From these, four (50.0% of eight patients) received three to eight antibiotics and four (50.0% of eight patients) received three to four antibiotics, respectively, suggesting that the curative with honey promotes a better recovery.

For drugs used in therapy of patients, it was observed that the group that was associated with honey curative has required fewer antibiotics and classes (penicilâmicos, cephalosporins, aminoglycosides and imidazole) compared to the group treated with usual curatives (penicilâmicos, cephalosporins, aminoglycosides, imidazoles, quinolones, glycopeptides, carbapenems and sulfas).

The pictures below show the evolution of post-surgical treatment of a patient, in what the honey has been used as an adjuvant to curatives in association with the drug treatment (Figure 3).



initial post-operative 15 days 23 days



43 days (suture injury) Final aspect of the treatment

Figure 3: Developments in the treatment of a patient who used honey in the curatives.

**CONCLUSION**

Among the eight cases that have been studied, the information suggests that the use of honey curatives on patients affected by Fournier's syndrome leads to the need of fewer types and classes of antibiotics; and also suggests that the length of stay and cost of patient treatment can be reduced if the syndrome is quickly diagnosed and if the honey is used as an adjuvant to curatives.

Financial Aid: UNISA.

**REFERÊNCIAS**

ALMEIDA, G.L; HILGERT, H. Gangrena de Fournier. **Rev. Tec - Científica do Grupo Hospitalar Conceição - Mom. & Perspect. Saúde,** Porto Alegre, v. 18, n. 1, p. 30-38, jan./jul. 2005.

ALVES, D.F.S. et al. Effects of Topical Application of the Honey of Melipona subnitida in Infected Wounds of Rats. **Rev. Col. Bras. Cir.** Natal, v. 35, n. 3, p. 188-192, maio/jun. 2008.

ARRUDA, H. O. Gangrena de Fournier. In: CURY, J; SIMONETTI, R; SROUGI, M. **Urgências em Urologia.** São Paulo: Sarvier, 1999. cap. 5, p. 40-43.

BORRELLI, M. Gangrena da Genitália Masculina. In: BORRELLI, M et all. Urgências Urológicas. São Paulo: Atheneu, 1985. cap. 15, p. 117-119.

CAPELHUCHNICK, P; CHIA-BIN, F; KLUG, W. A. Moléstia de Fournier - Estudo de 30 casos. Fatores que influem na Mortalidade. **Rev. Brasileira de Colo-Proctologia**, São Paulo, v. 12, n. 4, p. 115-118, out./dez. 1992.

CARDOSO, J.B; FÉRES, O. Gangrena de Fournier. **Medicina de Ribeirão Preto**, Ribeirão Preto, v. 40, n. 4, p. 493-499, out./dez. 2007.

COSTA, I.M.C. et al. Fasciíte Necrosante: Revisão com Enfoque nos Aspectos Dermatológicos. **Anais Brasileiro de Dermatologia**, Rio de Janeiro, v. 79, n. 2, p. 211-241, març./abr. 2004.

EKE, N. Fournier's Gangrene: A Review of 1726 cases. **Br J Surg,** Nigéria, v. 87, n. 6, p. 718-728, june 2000.

FERREIRA, E. et al. Curativo do Paciente Queimado: Uma Revisão de Literatura. **Rev. de Enfermagem USP,** Ribeirão Preto, v.37, n.1, p. 44-51, 2003.

GURDAL, M et al. Predisposing Factors and Treatment outcome in Fournier's Gangrene: Analysis of 28 cases. **Urol Int.** Turkey, v. 70, n. 1, p. 226-290, 2003.

HEJASE, M. J. et al. Genital Fournier's Gangrene: Experience White 38 patients. **Urology,** México, v. 47, n. 5, p. 734-739, 1996.

HERING, F. L. O. Emergências Geniturinárias não Traumáticas. In: HERING, F. L. O; SROUGI, M. **Urologia: diagnóstico e tratamento**. São Paulo: Roca, 1998. cap. 4, p. 185-186.

IAZZETTI, P.E; MANTOVANI M. Hiperoxia Hiperbárica em Infecções Graves e Sepse - Conceitos e Perspectiva. **Medicina Ribeirão Preto,** Ribeirão Preto, v. 31, n.1, p. 412-423, jul./set. 1998.

IMAD, M.T. et al. Lactobacillus gasseri: causing Fournier's Gangrene. **Scond J. Infected Dis**. Estados Unidos, v. 36, p. 501-503, 2004.

LIMA E.B. et al. O Papel da Oxigenoterapia no Tratamento da Gangrena Clostridiana e da Fasciíte Necrotizante. **J. Vasc. Br.** Santos, v. 2, n. 3, p. 220-224, 2003.

LIRA, E. F. et al. Gangrena de Fournier após Fistulectomia com bloqueio do Nervo Pudendo Interno: Relato de Caso. **Rev. Brasileira de Colo-Proctologia,** São Paulo, v.18, n.4, p. 249-252, out./dez. 1998.

MIORIN, Patricia Laguna. Composição Química e Atividade Anribacteriana do Mel e da Própolis de *Apis Mellifera e Tetragonisca angustula* contra *Staphylococus aureu*s. 2002. 110f. Dissertação (mestrado em Microbiologia) - Faculdade de Ciências Biomédicas, Universidade de São Paulo, São Paulo, 2002.

MOREIRA, R. F. A; DE MARIA, C. A. B. Glicídios no Mel. **Quim. Nova**, Rio de Janeiro, v. 24, n. 4, p. 516-525, jul./agost. 2001.

NADAL, S.R. et al. Síndrome de Fournier. **Revista do Colégio Brasileiro de Cirurgiões**, São Paulo, v. 19, n. 3, p. 104-107, maio/jun. 1992.

NISBET, A. A; THOMPSON, I.A. Impacto of Diabetes Mellitus on the presentation and outcomes of Fournier's Gangrene. Urology, Texas, v. 60, n. 5, p. 775-779, june 2002.

PEREIRA, F.M. et al. Produção de Mel. Net, Terezina, jul. 2003. Disponível em: http://www.sistemadeprodução.cnptia.embrapa.br/FontesHTML/Mel/SPMel/index.htm. Acesso em 07 set. 2006.

SOBRADO, C. N. et al. Gangrena de Fournier pós-hemorroidectomia. **Rev. Brasileira de Colo-Proctologia,** São Paulo, v.17, n. 3, p. 198-202, jul./set. 1997.

STEINMAN, E. et al. Síndrome de Fournier: Avaliação e Tratamento inicial. **Rev. Ass. Médica do Brasil,** São Paulo, v. 38, n. 4, p. 209-213. 1992.

WIESE, Helmuth. **Apicultura Novos Tempos.** Guaíba: Agropecuária, 2000. 424 p.

ZANELLI, G. et al. Síndrome de Fournier em pediatria: relato de caso**. Rev. méd. Aeronaut. Bras**., v. 41, n. 2, p. 109-11, jul./dez. 1991.

RUA DESEMBARGADOR ALTENFELDER SILVA, 130
VILA LAJEADO – JAGUARÉ – SÃO PAULO – SP CEP: 05338-090
reginash@gmail.com

**FOURNIER'S SYNDROME: USUAL CURATIVE X CURATIVE WITH HONEY ASSOCIATED WITH DRUG THERAPY, SÃO PAULO, SP, 2005 TO 2007.**

**ABSTRACT**

Fournier's syndrome, a rare disease that starts with an infection and necrotizing process of subcutaneous tissue, may have different origins, urogenital, anorectal and skin and were due to diseases arising from those areas. The infection is polymicrobial, caused by the synergism between bacteria. Signs and symptoms are pain, swelling, erythema, crackle and tissue necrosis of the fascia, which in some cases appears later fever and purulent secretion foul-smelling abscess already formed in the initial process. The treatment is based on the stabilization of the patient, the surgical debridement and drainage of the area involved and administration of broad spectrum antibiotics, and a cephalosporin 3rd generation or penicillin, an aminoglycoside or metronidazole for anaerobes. The dressing of the site is essential after debridement to remove pus, fibrin tissue and aids in the healing process. Many authors indicate the dressing with honey on the spot and an adjunct to treatment, and has proved effective in helping control swelling and inflammation, death of pathogenic bacteria, debridement of necrotic spots and better wound

healing, but this was not takes place in Brazil. The objective of this study was to collect and monitor cases of patients affected by Fournier's syndrome and to verify the therapeutic activity of honey as an adjunct to healing associated with drug treatment. Among the eight cases studied, the data suggest that the use of honey dressings on patients with this syndrome Fournier, reduces the use of antibiotics in terms of asset type and class, suggest that the length of stay and cost of treatment of patients can be reduced if the condition is diagnosed quickly and if used honey as an adjunct to healing.

**KEY WORDS:** Syndrome Fournier, Fournier's gangrene, topics with honey dressings.

**SYNDROME DE FOURNIER: TRAITEMENT USUEL X TRAITEMENT AVEC MIEL ASSOCIÉ AU TRAITEMENT MÉDICAMENTEUX, SÃO PAULO, SP, 2005 - 2007.**

**RÉSUMÉ**

Syndrome de Fournier est une pathologie rare qu'il s'initie avec une forme infectieuse et necrosante des nerfs, peut avoir diverses origines, urogenitalles, anorretalles et cutanées, sont lês causes decorantes du pathologie qui s `involve avec ces regions. L'infection est polimicrobienne, cause par synergisme entre les bactéries. Les signaux et les symtomes sont : avoir mal partout, oeudemes, eritema, crépitation dês nerfs, des nerfs faciaux, sur lesquels certains cãs apparecente posterieurement cadre de fièvre et sortie de sécrétion purulente avec odeur faitent de abcesse déjà formes au processus initial. Le traitement est basè sur èstabilisation clinique du malade, sur l `operation cirurgicale avec drenagène du region atteinte et aussi administration dês antibiotic spectre, une cefalosporina de troisieme génération ou une pénicilline, une aminoglicosídeo ou une metronidazol pour anaérobies. Le traitement de la region est essentiel après l`operation la sécrétion purulenta, des nerfs de fibres et auxiliaire sur le processus de cicatrisation. Beaucoup d'auteurs indiquent le traitement avec miel du local envoie adjudant au traitement, qui ont demonstres leur efficacite du contrôle des oudemes et du processus inflammatoire, la mort des bactéries pathogenique, l`ouverture de points necrótiques et une meilleur cicatrisation du blessure, pourraint en même temps pás être possible au Brésil. L'objectif du travail était de lever et accompagner lês cas des malades atteintes par le Syndrome de Fournier et vérifier l'activité thérapeutique du miel comment utiliser lês medicamentes associés au traitement. Entre lês huite cãs etdiès, les données obtenues suggèrent que les medicaments avec miel au malades atteintes par le Syndrome de Fournier, diminue l'utilisation des antibiotiques em termes de type d'active et classe ; suggèrent aussi que le temps d'internation et Le prix du traitement des malades peuvent être réduits si l`infection est rapidement diagnostiquée et si possible utiliser Le miel comme stimulant aux medicaments.

**MOSTS CLEFS**: Syndrome de Fournier, de Gangrena de Fournier, Medicaments typique avec miel.

**SÍNDROME DE FOURNIER: TOCADOR HABITUALES X QUE VESTÍA GENERALMENTE QUE VESTÍA CON LA MIEL SE ASOCIÓ AL TRATAMIENTO MEDICAMENTOSO, SÃO PAULO, SP, 2005 - 2007.**

**RESUMEN**

El síndrome de Fournier es una patología rara que está iniciado con un proceso infeccioso y del necrotizante de telas subcutáneas, pudiendo tener orígenes diversos, anorrectal urogenital, cutáneo y, siendo las causas desde de patologías implicados con estas áreas. La infección es polimicrobiana, causado para el sinergismo entre las bacterias. Las señales y los síntomas son: dolor, edema, eritema, crujido de telas y necrosis de los fascia, donde en algunos casos aparece cuadro de la fiebre y de la salida de la secreción del purulenta más adelante con el olor del fétido del absceso formado ya en el proceso inicial. El tratamiento se basa en la estabilización clínica del paciente, en el desbridamiento quirúrgico con el drenaje de la administración contratada del área y del antibiótico del espectro ancho, siendo un cefalosporina de la generación 3º o de la penicilina, un aminoglucósido o metronidazol para los anaerobios. La preparación del lugar es esencial después del desbridamiento para la tela, del retiro de la secreción del purulenta del fibrina y de ayudas en el proceso del curación. Muchos autores indican la preparación con la miel en el lugar, siendo ayudante al tratamiento, que ha demostrado para ser el asistir eficiente al control del edema y del proceso inflamatorio, muerte de las bacterias patógenas, desbridamiento de los puntos de los necróticos y un curación mejor de la herida, al menos iguales no si de la que está en el Brasil. El objetivo del trabajo era plantear y seguir casos de los acometidos de los pacientes para el síndrome de Fournier y verificar la actividad terapéutica de la miel pues el coadyuvante a las preparaciones se asocia al tratamiento por drogas. Entre los ocho casos estudiados, los datos conseguidos sugieren que el uso de preparaciones con la miel en los acometidos de los pacientes para el síndrome de Fournier, disminuya el uso antibiótico en términos de tipo de activo y de sala de clase; sugieren a pesar de la época de la internación y el coste del tratamiento de los pacientes pueden ser reducidos si la patología está rápidamente diagnosticados y miel pues el coadyuvante a las preparaciones habrá sido utilizado.

**PALABRAS-CLAVE:** Síndrome de Fournier, Gangrena tópico de Fournier, preparaciones con la miel.

**SÍNDROME DE FOURNIER: CURATIVO USUAL X CURATIVO COM MEL ASSOCIADOS AO TRATAMENTO MEDICAMENTOSO, SÃO PAULO, SP, 2005- 2007.**

**RESUMO**

Síndrome de Fournier é uma patologia rara que se inicia com um processo infeccioso e necrosante dos tecidos subcutâneos, podendo ter diversas origens, urogenital, anorretal e cutânea, sendo as causas decorrentes de patologias envolvidas com essas áreas. A infecção é polimicrobiana, causada pelo sinergismo entre as bactérias. Os sinais e sintomas são: dor, edema, eritema, crepitação dos tecidos e necrose das fáscias, onde em alguns casos aparece posteriormente quadro de febre e saída de secreção purulenta com odor fétido do abscesso já formado no processo inicial. O tratamento baseia-se na estabilização clínica do paciente, no desbridamento cirúrgico com drenagem da área comprometida e administração de antibióticos de largo espectro, sendo uma cefalosporina de 3º geração ou penicilina, um aminoglicosídeo ou metronidazol para anaeróbios. O curativo do local é essencial após o desbridamento para remoção de secreção purulenta, de tecido de fibrina e auxilia no processo de cicatrização. Muitos autores indicam o curativo com mel no local, sendo um adjuvante ao tratamento, que tem demonstrado ser eficaz auxiliando no controle do edema e do processo inflamatório, morte das bactérias patogênicas, desbridamento de pontos necróticos e melhor cicatrização da ferida, porém o mesmo não se dá no Brasil. O objetivo do trabalho foi levantar e acompanhar casos de pacientes acometidos pela Síndrome de Fournier e verificar a atividade terapêutica do mel como adjuvante aos curativos associados ao tratamento medicamentoso. Dentre os oito casos estudados, os dados obtidos sugerem que a utilização de curativos com o mel em pacientes acometidos pela Síndrome de Fournier, diminui a utilização de antibióticos em termos de tipo de ativo e classe; sugerem ainda que o tempo de internação e custo do tratamento dos pacientes pode ser reduzido se a patologia for rapidamente diagnosticada e se for utilizado mel como adjuvante aos curativos.

**PALAVRAS CHAVES:** Síndrome de Fournier, Gangrena de Fournier, curativos tópicos com mel.

PUBLICAÇÃO NO FIEP BULLETIN ON-LINE: http://www.fiepbulletin.net/80/a1/220